



Case Report

Desmoid tumor of the Left Abdominal Wall: A Rare Case Report

 Muhammad Haider Ali¹, Muhammad Waqas¹, Hamza Khan Toru², Shandana Khan¹, Zakia Sultana¹ and Javeria¹
¹Department of Surgery, Hayatabad Medical Complex, Peshawar, Pakistan

²Department of Surgery, Khyber Teaching Hospital, Peshawar, Pakistan

ARTICLE INFO

Key Words:

Desmoid, Fibromatosis, Fibroadenoma

How to Cite:

 Haider Ali, M. ., Waqas, M. ., Khan Toru, H. ., Khan, S. ., Sultana, Z. . & ., J. (2023). Desmoid Tumor of the Left Abdominal Wall: A Rare Case Report: Desmoid tumor of the Left Abdominal Wall. *Pakistan Journal of Health Sciences*, 4(02).

<https://doi.org/10.54393/pjhs.v4i02.542>

*Corresponding Author:

Muhammad Haider Ali

 Department of Surgery, Hayatabad Medical Complex,
 Peshawar, Pakistan
haidu.khan00.ha@gmail.com
Received Date: 2nd February, 2023Acceptance Date: 20th February, 2023Published Date: 28th February, 2023

ABSTRACT

Desmoid tumors are the type of tumors that are infrequent. However, Desmoid tumors can invade in nearby areas and can re-appear even after excision. They can reach the abdominal areas and can result in pain and swelling. The author presents a case of Desmoid tumors in a 24 years old female involving the rectus sheath. **Case Summary:** We present a case of 24 year old woman initially diagnosed with fibroadenoma of the right breast. After a month of the procedure, the patient complained of nausea, pain and cramping in the left abdominal area. She was referred to us for further evaluation of the growing mass in the left abdominal area. A Trucut Biopsy revealed an abdominal mass in the left upper quadrant about 5x5cm hard in consistency. A desmoid tumor was revealed in the diagnosis. She underwent wide local excision. **Conclusions:** Desmoid tumors are a rare type of tumor. These types of tumors arise most commonly in the upper limb, lower limb and in the popliteal region. Our case presents a representation of the tumor in the abdominal region particularly rectus sheath. MRI and CT scan can be helpful in diagnosis of these tumors but histological findings are necessary. Our case outlines the importance of identification of desmoid tumors in a timely manner and also the symptoms that it presents with. These tumors are to be treated with surgical excision with follow up every two to four weeks.

INTRODUCTION

Desmoid tumors account for the rarest type of benign tumors. these types of tumors can occur sporadically, and it mainly includes the involvement of the shoulder, abdominal cavity and in lower limbs (popliteal fossa). They can invade the nearby tissues and can cause discomfort including swelling and pain in the abdominal area. Rectus sheath can be involved and may require surgical excision. According to Weschenfelder *et al.*, in 2015 it was firstly described by MacFarlane in 1832 and was later named desmoid tumor. The term "desmoid" was attributed to these tumors by Muller in 1838 [1]. The chief complaints of the patients with desmoid tumors includes swelling and pain along with nausea and numbness in the areas effected with these types of tumors. It occurs commonly in females during the reproductive years of their lives. According to Choi *et al.*, the definite etiology of desmoid tumors,

whether pregnancy-associated or otherwise, is currently unknown [2]. It has been found that the hormonal and immunological changes occurring during pregnancy and post-partum contribute to the formation of these tumors in females. According to Johner *et al.*, the local effect due to the mechanical stress from a gravid uterus may also contribute to the occurrence of a desmoid tumor [3]. MRI and CT Scan can be helpful in the diagnosis of these tumors but a histological finding can best describe the diagnosis [4]. Reoccurrence rates have been reported locally, and surgically excised cases have been reported to reoccur in over two-thirds of cases [5-7]. MRI and CT Scans can be helpful in the diagnosis of these tumors but a histological finding can best describe the diagnosis [8]. Surgical excision is best recommended as a treatment option for desmoid tumors. However, according to a study by Alman *et*

al., surgery had a favorable recurrence rate (15%), but some recurrences were associated with a significant treatment burden. A multidisciplinary program can be beneficial for good treatment effects [9]. Cryotherapy and radiotherapy are also considered alternative therapy in treating Desmoid tumors [10-12]. The author presents a case of Desmoid tumors in a 24 years old female involving the rectus sheath in the left upper quadrant.

Case Presentation

A 24-year-old female patient presented with a mass in R) abdomen region on anterior aspect that on examination was firm in consistency was smooth and mobile in nature. The lesion was about 5*5 cm in dimension and the overlying skin was unaffected. Ultrasound was advised and it showed a round well circumscribed, heterogeneous mass was noticed and was queried as being a Desmoid lesion and advised CT scan to know the extent of the lesion on CT scan it was showing a lesion of 8*6 cm and having well defined margins but involving rectus abdominis muscle. Decision was made to excise the lesion and on excision biopsy the lesion was sent for histopathology that turned out to be Desmoid lesion. The patient underwent a complete surgical excision of the tumor. The patient has been discharged from the hospital on the 2nd post-operative day with an uneventful recovery; she was in good health and two weeks follow up was given to the patient. ON followup patients stitches were removed and patient was completely free of any complaints.

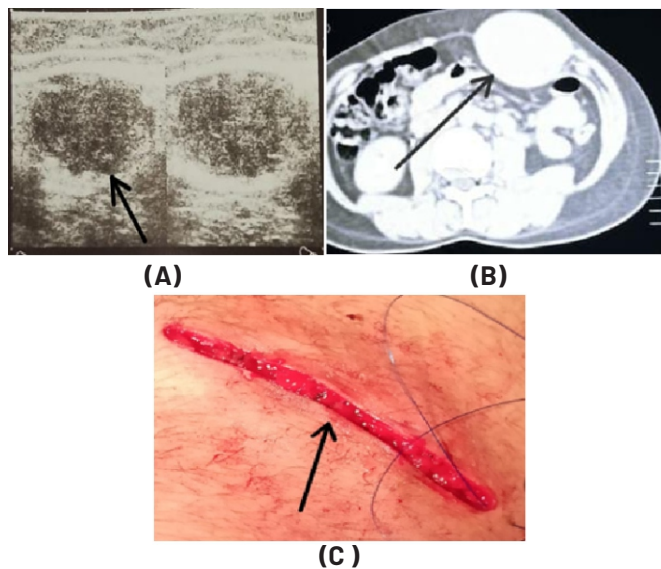


Figure 1: (A) Ultrasound of lesion (B) CT SCAN of Lesion (C) Operative site

DISCUSSION

Desmoid tumor, or aggressive fibromatosis, is a benign mesenchymal monoclonal proliferations arising from the connective tissue of the muscle and overlying the

aponeurosis or fascia. In this case it was found in the left upper quadrant of the abdominal cavity in the rectus sheath. The chief complaints of the patients with desmoid tumors includes swelling and pain along with nausea and numbness in the areas effected with these types of tumors. Genetic factors including mutations in the CTNNB1 gene or in the APC gene are largely responsible for desmoid tumors [5]. The development of Desmoid tumors occurs more frequently in women. It commonly occurs during the reproductive years of a women's life, specially during pregnancy and after child birth when the mother is lactating. The gold standard to evaluate the augmentation of Desmoid tumors is an MRI [4]. MRI can be useful in distinguishing desmoid tumor from other malignancies of the breast, as well as revealing the extent of the tumor and relationship to adjacent structures. Desmoid tumors are a rare type of tumor. These types of tumors arise most commonly in the upper limb, lower limb and in the popliteal region. Our case presents a representation of the tumor in the abdominal region particularly rectus sheet. MRI and CT scan can be helpful in diagnosis of these tumors but histological findings are necessary. Our case outlines the importance of identification of desmoid tumors in a timely manner and their presentation in association with fibroadenoma and also the symptoms that it presents with. These tumors are to be treated with surgical excision with follow up every two to four weeks.

CONCLUSIONS

In conclusion, desmoid tumors are a rare and complex type of tumor that can present in various regions of the body, including the limbs and the abdominal area. Early recognition of the symptoms and proper diagnostic techniques, such as MRI and CT scans with histological confirmation, are crucial for effective treatment. Surgical excision is the preferred treatment option for desmoid tumors, and close follow-up and monitoring are essential for successful outcomes.

Conflicts of Interest

The authors declare no conflict of interest.

Source of Funding

The authors received no financial support for the research, authorship and/or publication of this article.

REFERENCES

- [1] Weschenfelder W, Lindner R, Spiegel C, Hofmann GO, Vogt M. Desmoid tumor of the popliteal fossa during pregnancy. *Case Reports in Surgery*. 2015 Feb; 2015: 1-4. doi: 10.1155/2015/262654
- [2] Choi SH, Lee JH, Seo BF, Kim SW, Rhie JW, Ahn ST. Desmoid tumor of the rectus abdominis muscle in a postpartum patient. *Archives of Plastic Surgery*. 2012

- Jul; 39(04): 439-41. doi: 10.5999/aps.2012.39.4.439
- [3] Johner A, Tiwari P, Zetler P, Wiseman SM. Abdominal wall desmoid tumors associated with pregnancy: current concepts. *Expert Review of Anticancer Therapy*. 2009 Nov; 9(11): 1675-82. doi: 10.1586/era.09.98
- [4] Mabrouk MY, Bouzayan L, Malki S, Jabi R, Bennani A, Bouziane M. Desmoid tumor of the anterolateral abdominal wall: a rare case report. *Annals of Medicine and Surgery*. 2021 Oct; 70: 102804. doi: 10.1016/j.amsu.2021.102804
- [5] Colangeli S, Parchi P, Andreani L, Beltrami G, Scoccianti G, Sacchetti F, et al. Cryotherapy efficacy and safety as local therapy in surgical treatment of musculoskeletal tumours. A retrospective case series of 143 patients. *Journal of Biological Regulators and Homeostatic Agents*. 2018 Nov; 32(6 Suppl. 1): 65-70.
- [6] Goodlad JR, Fletcher CD, Smith MA. Surgical resection of primary soft-tissue sarcoma: incidence of residual tumour in 95 patients needing re-excision after local resection. *The Journal of bone and joint surgery. British Volume*. 1996 Jul; 78(4): 658-61. doi: 10.1302/0301-620X.78B4.0780658
- [7] Phillips SR, A'Hern R, Thomas JM. Aggressive fibromatosis of the abdominal wall, limbs and limb girdles. *Journal of British Surgery*. 2004 Dec; 91(12): 1624-9. doi: 10.1002/bjs.4792
- [8] Turner B, Alghamdi M, Henning JW, Kurien E, Morris D, Bouchard-Fortier A, et al. Surgical excision versus observation as initial management of desmoid tumors: A population based study. *European Journal of Surgical Oncology*. 2019 Apr; 45(4): 699-703. doi: 10.1016/j.ejso.2018.09.015
- [9] Alman B, Attia S, Baumgarten C, Benson C, Blay JY, Bonvalot S, et al. The management of desmoid tumours: a joint global consensus-based guideline approach for adult and paediatric patients. *European Journal of Cancer*. 2020 Mar; 127: 96-107. doi: 10.1016/j.ejca.2019.11.013
- [10] Lazar AJ, Tuvin D, Hajibashi S, Habeeb S, Bolshakov S, Mayordomo-Aranda E, et al. Specific mutations in the β -catenin gene (CTNNB1) correlate with local recurrence in sporadic desmoid tumors. *The American Journal of Pathology*. 2008 Nov; 173(5): 1518-27. doi: 10.2353/ajpath.2008.080475
- [11] Hennuy C, Defrère P, Maweja S, Thiry A, Gennigens C. Bilateral breast desmoid-type fibromatosis, case report and literature review. *Gland Surgery*. 2022 Nov; 11(11): 1832-41. doi: 10.21037/gS-22-271
- [12] Naama H, Ludmila F, Ahuva G, Eran S. DeSMoiD tuMor MASQuerADiNg AS fiBroADeNoMA. CASe rePort AND

reView of LiterAture. Medical Connections|Conexiuni Medicale. 2013 Mar; 1(29): 67-70.