



Case Study

Abdominal Ectopic Pregnancy: Surgical Management in Low-Resource Settings

Rida Asghar¹, Aqsa Aman¹, Umm E Aiman Saleem¹, Mohammad Osama², Rakhshinda Inam¹ and Muhammad Waqas²¹Department of Gynaecology and Obstetrics, Gomal Medical College, Dera Ismail Khan, Pakistan²Gomal Medical College, Dera Ismail Khan, Pakistan

ARTICLE INFO

Keywords:

Abdominal Ectopic Pregnancy, Laparotomy, Obstetric Emergency, Ultrasound Diagnosis

How to Cite:Asghar, R., Aman, A., Saleem, U. E. A., Osama, M., Inam, R., & Waqas, M. (2025). Abdominal Ectopic Pregnancy: Surgical Management in Low-Resource Settings: Abdominal Ectopic Pregnancy: Surgical Management. *Pakistan Journal of Health Sciences*, 6(5), 302-306. <https://doi.org/10.54393/pjhs.v6i5.3021>***Corresponding Author:**Mohammad Osama
Gomal Medical College, Dera Ismail Khan, Pakistan
chambersburg56@gmail.comReceived Date: 29th March, 2025Revised Date: 20th May, 2025Acceptance Date: 24th May, 2025Published Date: 31st May, 2025

ABSTRACT

Abdominal ectopic pregnancy (AEP) is a rare and potentially life-threatening condition in which a fertilized ovum implants within the peritoneal cavity outside the uterine structures. It accounts for approximately 1% of all ectopic pregnancies and poses significant diagnostic and management challenges. AEP is a rare but serious obstetric emergency requiring high clinical suspicion for early diagnosis. Prompt imaging and appropriate surgical intervention are crucial in preventing maternal morbidity and mortality. We hereby report a case of a 42-year-old Gravida5 Para4 Alive1, a 17-week pregnant woman from a remote rural area presented with shock and sudden lower abdominal pain for 5 hours. Abdominal ultrasound revealed an abdominal ectopic pregnancy with the fetus in the right iliac fossa. Due to hemodynamic instability, an emergency laparotomy was performed, revealing a 17-week male fetus in the peritoneal cavity with 1500 mL of hemoperitoneum. The placenta was attached to the right fallopian tube, necessitating a salpingectomy. Postoperative recovery was uneventful without complications. This case highlights the importance of considering AEP in differential diagnoses of atypical abdominal pain in pregnancy and underscores the role of multidisciplinary management for optimal patient outcomes.

INTRODUCTION

Abdominal Ectopic pregnancy (AEP) is an extremely rare condition, accounting for approximately 0.6–4% of all ectopic pregnancies [1]. The most frequent locations for ectopic implantation are the ampullary (70%), isthmic (12%), fimbrial (11%), and ovarian (3.2%) regions [2, 3]. AEP is a potentially life-threatening condition where a pregnancy develops outside the uterus, either primarily or secondarily, in the abdominal cavity [4]. A primary AEP occurs when the fertilized ovum is directly implanted in the abdominal cavity. The fallopian tubes and ovaries are unharmed in these situations. On the other hand, when an extra-uterine tubal pregnancy ruptures or aborts and is re-implanted inside the abdomen, this is known as a

secondary AEP [5]. Before 20 weeks of amenorrhea, abdominal ectopic pregnancy is considered to be early; after 20 weeks, it is considered late. The patient is constantly at risk for both maternal and fetal problems [6]. Maternal complications can occur in the antepartum, peripartum or postpartum periods. These complications include spontaneous separation of the placenta leading to massive hemorrhage, shock, disseminated intravascular coagulation, organ failure, and death [7]. Due to inadequate prenatal care, low socioeconomic patient status, and a lack of sufficient medical resources, diagnoses can often go unnoticed in low-resource settings [8, 9].

Case Report

A 42-year-old woman, Gravida5 Para4 A11, presented to the Emergency Department of Women and Children Hospital, Dera Ismail Khan, in hemorrhagic shock. Ethical approval for the publication of this case report was obtained from the Institutional Ethical Review Committee of Gomal Medical College, Dera Ismail Khan, under reference number 224/GJMS/JC. The report was prepared in accordance with the ethical standards and clinical research guidelines established by the Declaration of Helsinki. Written informed consent was obtained from the patient's family prior to the preparation and submission of this report. The family was fully informed about the nature and purpose of the case report, the inclusion of anonymized clinical data and surgical images, and the intended publication in a peer-reviewed medical journal. The consent process involved clear communication in a language they understood, and the family was given sufficient time to ask questions and make an informed decision. The patient's identity has been protected by ensuring that no personal details or facial features are disclosed. All images and data have been carefully anonymized to maintain confidentiality. The authors confirm that publication of the case report respects the patient's dignity and privacy and that all necessary approvals and written consents were obtained before submission. She had a 15-year history of consanguineous marriage and previous adverse obstetric outcomes, including three early neonatal deaths due to sustained birth trauma. Her medical history included chronic pelvic inflammatory disease and a family history of tubal pregnancy. She reported 17 weeks of gestational amenorrhea and presented with a sudden onset of severe lower abdominal pain lasting five hours. She had been referred from a remote rural tribal area, leading to a delay in seeking medical attention. During the history taking, the pregnancy remained undiagnosed due to the patient's history of irregular menstrual cycles over the last few years. Initially, she visited a local healthcare facility, where she was diagnosed with pregnancy; however, due to a lack of trained health personnel and adequate facilities at that time, she was quickly transferred to our facility. On examination, her vital signs were: BP 80/50 mmHg, HR 130 bpm, RR 26/min, with marked pallor (++). Chest and heart sounds were normal. Abdominal examination revealed a distended, tender abdomen with signs of peritonitis. Fetal parts were not palpable clinically, and fetal heart sounds were inaudible. Pelvic examination showed a uterus that was not separately palpable, a normal cervix with a closed Os, and cervical motion tenderness. Due to the patient's deteriorating condition, a detailed obstetric and Doppler ultrasound, MRI or CT scan could not be performed. However, an urgent obstetric ultrasound revealed a 17-week extra-uterine male fetus in the right iliac fossa with significant free fluid in the abdomen. Laboratory investigations showed Hb: 8.5 g/dL and elevated β -hCG,

consistent with a second-trimester pregnancy. Given her worsening hemodynamic instability, an emergency exploratory laparotomy was planned. During the initial resuscitation and stabilization of the patient before emergency laparotomy, the team first secured the airway, evaluated breathing, and made sure the patient had enough circulation throughout the initial resuscitation and stabilization. The insertion of two large-bore (18G) IV lines allowed for quick fluid resuscitation. Rapid administration of crystalloids, such as Ringer's lactate or normal saline, was initiated to address hemodynamic instability and blood loss. Additionally, as needed, blood products such as packed red blood cells (RBC), fresh frozen plasma (FFP), and Platelets were started. Vital indicators such as blood pressure, oxygen saturation, heart rate, and urine output were all regularly monitored by the team. Throughout this process, preparation for emergency laparotomy continues with ongoing fluid and blood product resuscitation during the transfer to the operating room. Communication with the surgical team and anesthesiologist was maintained to ensure coordinated care, with all interventions and observations carefully documented. She was transfused with three units of blood during surgery. Intraoperatively, around 1500 mL of hemoperitoneum was found, along with a 17-week male fetus floating freely in the peritoneal cavity. The placenta was densely adherent to the right fallopian tube, giving the clinical picture of secondary ectopic pregnancy, and was the source of active bleeding. A salpingectomy was performed, along with tubal ligation with consent of the family; hemostasis was secured, and the peritoneal cavity was thoroughly irrigated. The placenta was carefully detached from the tubal attachment to prevent excessive bleeding, as it was a clinically complete evacuation of the foetus, placental membrane and placenta, ensuring no residual tissue was left behind. The patient had an uneventful recovery, with gradual stabilization of vital signs. On follow-up visit on day 12 of the procedure, the urine pregnancy test was done and was found to be negative, with serial serum β -hCG levels for the next three weeks till stabilization of it to the baseline. Densely adherent placenta is shown in Figure 1.

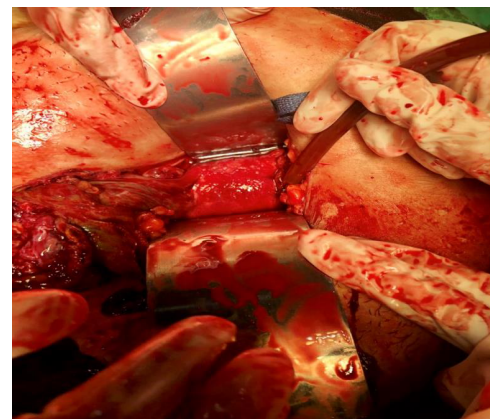

Figure 1: Image of A Densely Adherent Placenta

Extra-uterine fetus lying in the right iliac fossa is given a full urinary bladder, as shown in Figure 2.

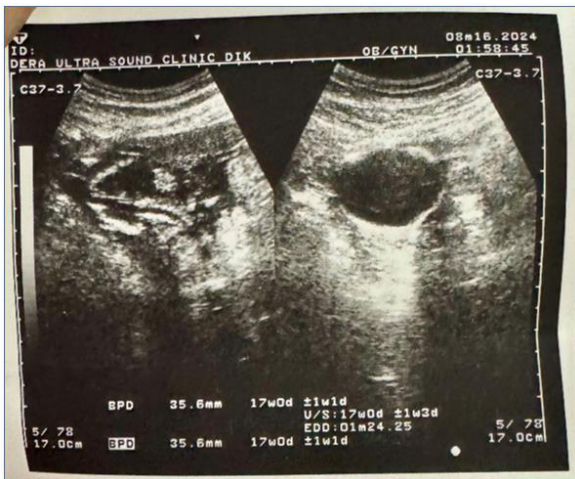

Figure 2: Extra-Uterine Fetus Lying in the Right Iliac Fossa in a View of Full Urinary Bladder

The surgical specimen consisted of a well-formed 17-week male fetus, placenta, and associated tissues, as shown in Figure 3.

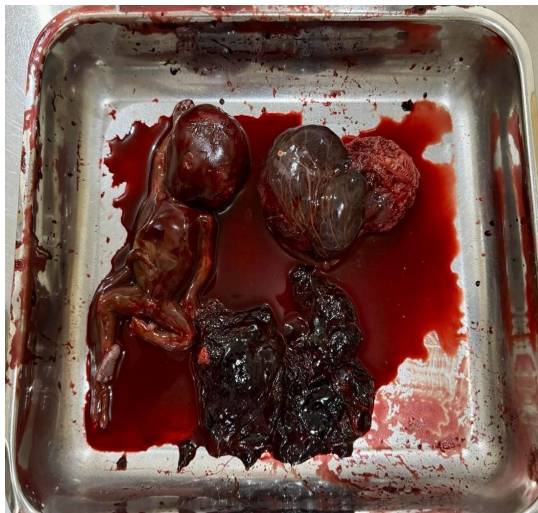


Figure 3: The Surgical Specimen Consisting of a Well-Formed 17-Week Male Fetus, Placenta, and Associated Tissues

DISCUSSION

Abdominal Ectopic pregnancy (AEP) is unique among ectopic pregnancies in that it can potentially advance to full term [10]. AEP is a rare and high-risk form of ectopic pregnancy, associated with significantly increased complications and mortality for the mother [11]. Survival rates for fetuses in abdominal pregnancies are extremely low, and those who do survive often experience severe birth defects and high perinatal mortality, with fetal mortality rates ranging from 40% to 90% [12]. Maternal Age over 35, pelvic inflammatory disease, endometriosis, smoking, assisted reproduction, a history of fallopian tube inflammation or abnormal shape, a history of ectopic pregnancy, a history of getting pregnant while using an

intrauterine device, and scarring from pelvic surgery are risk factors for ectopic pregnancy. However, there are no known risk factors for half of the women with ectopic pregnancy diagnoses [13]. Early diagnosis is crucial for minimizing morbidity, enhancing the success of subsequent treatments, and reducing long-term complications. Unfortunately, even in the modern era, an ectopic pregnancy may remain undiagnosed or, worse, misdiagnosed, putting a woman's life at risk [14]. Early ultrasound is crucial in diagnosing cases with suspected EP or AEP [15]. Pelvic ultrasound remains the most effective diagnostic tool for detecting adnexal or peri-uterine pregnancies. The detection rate improves when combined with a quantitative serum β -hCG measurement. For locating abdominal pregnancies, MRI is the preferred method, though in emergencies, CT is the quickest option [16]. A recent comparative study by Khan *et al.*, compared the results of surgical and medical treatment for ectopic pregnancy patients. According to the study, surgical management had a 95% success rate, while medical management with methotrexate had an 85% success rate. However, compared to medical management (10%), surgical interventions were linked to a marginally higher complication rate (12%) [17]. The surgical approach for abdominal pregnancy depends on several factors, including the pregnancy location, the patient's condition, surgical technique, the surgeon's experience, and available resources. Laparoscopy is preferred in stable patients with early diagnosis and experienced surgeons [18]. Comparing laparoscopy versus laparotomy, the former led to a shorter operating time, less blood loss, and fewer hospital days [19]. However, if the patient's condition is hemodynamically unstable with an ultrasound finding of fluid interpreted as hemoperitoneum, laparotomy is urgent to terminate the pregnancy and control the bleeding as found in this case [20].

CONCLUSIONS

Abdominal ectopic pregnancy (AEP) is a rare but serious obstetric emergency requiring high clinical suspicion for early diagnosis. Prompt and accurate diagnosis is crucial in minimizing the risks and complications associated with abdominal pregnancy, ultimately reducing mortality and morbidity rates. This case highlights the importance of considering AEP in differential diagnoses of atypical abdominal pain in pregnancy and underscores the role of multidisciplinary management for optimal patient outcomes. This case report highlights the critical importance of timely intervention in resource-limited settings while managing abdominal pregnancy, providing valuable surgical insights that can enhance our understanding and inform our approach to caring for such patients in clinical practice.

Authors Contribution

Conceptualization: RA, AA, MO

Methodology: RI

Formal analysis: RA

Writing review and editing: RA, AA, UEAS, MO, RI, MW

All authors have read and agreed to the published version of the manuscript

Conflicts of Interest

All the authors declare no conflict of interest.

Source of Funding

The author received no financial support for the research, authorship and/or publication of this article.

REFERENCES

- [1] Fessehaye A, Gashawbeza B, Daba M, Arusi M, Terefe T. Abdominal ectopic pregnancy complicated with a large bowel injury: a case report. *Journal of Medical Case Reports*.2021 Dec; 15: 1-5. doi: 10.1186/s13256-021-02713-9.
- [2] Durden JA, Burlison SL, Pigott DC, Gullett JP, Thompson M. Abdominal Ectopic Pregnancy: A Case Report of an Uncommon Complication of Pregnancy Without Prenatal Care. *Cureus*.2024Sep;16(9).doi: 10.7759/cureus.68478.
- [3] Bouyer J, Coste J, Fernandez H, Pouly JL, Job-Spira N. Sites of ectopic pregnancy: a 10-year population-based study of 1800 cases. *Human Reproduction*. 2002 Dec; 17(12): 3224-30. doi: 10.1093/humrep/ 17. 12.3224.
- [4] Dunphy L, Boyle S, Cassim N, Swaminathan A. Abdominal Ectopic Pregnancy. *British Medical Journal Case Reports*.2023 Sep; 16(9): e252960. doi: 10.1136/bcr-2022-252960.
- [5] Aref Hamam Y, Zimmo M, Alqeeq BF, Hijazi YM, Hamam M, Al-Hajjar M. Advanced secondary abdominal ectopic pregnancy with live fetus at 26 weeks' gestation following in vitro fertilisation: A case report. *SAGE Open Medical Case Reports*.2024 Jan; 12: 20 50 313X241226776. doi: 10.1177/2050313X241226776.
- [6] Aboubakari AS, Ajavon DR, Dossouvi T, Logbo-Akey KE, Dagbé M, Akpadza K. Ruptured abdominal pregnancy at 35 weeks with live child-a case study at Kara university hospital (Togo). *The New Indian Journal of Obgyn*.2019; 5(2): 154-8. doi: 10.21276/obgyn.2019.5.2.19.
- [7] Paluku JL, Kalole BK, Furaha CM, Kamabu EM, Mohilo GM, Kataliko BK et al. Late abdominal pregnancy in a post-conflict context: case of a mistaken acute abdomen-a case report. *BioMed Central Pregnancy and Childbirth*.2020 Dec; 20: 1-6. doi: 10.1186/s12884-020-02939-3.
- [8] Mulisya O, Barasima G, Lugobe HM, Matumo P, Vahwere BM, Mutuka H et al. Abdominal pregnancy with a live newborn in a low-resource setting: A case report. *Case Reports in Women's Health*.2023 Mar; 37: e00 480. doi: 10.1016/j.crwh.2023.e00480.
- [9] Siati A, Berrada T, Kharbach A. Abdominal pregnancy with a healthy newborn: a new case. *Pan African Medical Journal*.2019Sep;34(1).doi:10.11604/pamj .2019.34.35.20169.
- [10] Mengistu Z, Getachew A, Adefris M. Term abdominal pregnancy: a case report. *Journal of Medical Case Reports*.2015 Dec; 9: 1-3.doi:10.1186/s13256-015-063 5-3.
- [11] Suryawan A, Rahardjo TM, Suparman E, Mahardhika JC. Right abdominal pregnancy with hemorrhagic shock after previous left tubal pregnancy: A case report. *SAGE Open Medical Case Reports*. 2023 Jun; 11:2050313X231180757.doi:10.1177/2050313X23118 0757.
- [12] Legesse TK, Ayana BA, Issa SA. Surviving fetus from a full-term abdominal pregnancy. *International Medical Case Reports Journal*.2023 Dec: 173-8. doi: 10.214 7/ I MCRJ.S403180.
- [13] Jahedbozorgan T, Mahmoudi A, Zaniyani FR. Unusual Abdominal Ectopic Pregnancy Implantation in the Vesicouterine Pouch: A Case Report. *Novelty in Biomedicine*. 2023 Jan; 11(1): 38-40.
- [14] Syed S, Malik AS, Naz T, Zahoor A, Ashraf A, Nawaz R. An Advanced Intact Tubal Ectopic Pregnancy with an Alive Foetus of 19 Weeks Gestation; A Rare Case Report. *Journal of The Society of Obstetricians and Gynaecologists of Pakistan*. 2024 Oct; 14(3): 365-70.
- [15] Tomaszek P, Hager L, Alluri A, Abukhaled M, Ali SN, Al-Hilali A et al. Abdominal Ectopic Pregnancy: A Case Report of an Uncommon Presentation and a Brief Review of the Literature. *Journal of Medical Case Reports*. 2024;5(1): 34-7.
- [16] Di Gennaro D, Damiani GR, Muzzupapa G, Stomati M, Cicinelli R, Gaetani M et al. Ectopic pregnancy: An overview. *Clinical and Experimental Obstetrics and Gynecology*.2022Nov;49(12):262.doi:10.31083/j .ceog4912262.
- [17] Shiravani Z, Atbaei S, Jahromi BN, Tafti MH, Alamdarloo SM, Poordast T et al. Comparing four different methods for the management of ectopic pregnancy: A cross-sectional study. *International Journal of Reproductive Biomedicine*.2022Apr21; 20(3): 177. doi: 10.18502/ijrm.v20i3.10709.
- [18] Hajji A, Toumi D, Laakom O, Cherif O, Faleh R. Early primary abdominal pregnancy: diagnosis and management. A case report. *International Journal of Surgery Case Reports*.2020Jan;73:303-6.doi:10.1016 /j.ijscr.2020.07.048.
- [19] Shaw SW, Hsu JJ, Chueh HY, Han CM, Chen FC, Chang YI et al. Management of primary abdominal pregnancy: twelve years of experience in a medical centre. *Acta obstetrica et gynecologica Scandinavica*.2007 Sep; 86(9): 1058-62. doi: 10.1080/00016340701434476.

- [20] Mamo A and Adkins K. Abdominal pregnancy: pathophysiology, diagnosis, and treatment. *Journal of Gynecologic Surgery*. 2022 Jun; 38(3): 193-6. doi: 10.1089/gyn.2022.0013.