



Original Article

Diagnostic Accuracy of Ultrasound for Benign and Malignant Hepatic Masses Taking Computed Tomography as Gold Standard

Arbia Aslam¹, Memona Nazir¹, Syed Zain ul Abidin¹, Zareen Fatima¹, Syed Muhammad Yousaf Farooq¹, Saad Zia¹, Waqar Ahmad¹, Nadia Adrees¹, Savaira Naeem¹, Areej Imtiaz¹, Manahil Fatima¹ and Ujala Rita¹

¹University Institute of Radiological Sciences & Medical Imaging Technology, The University of Lahore, Pakistan

ARTICLE INFO

Key Words:

Diagnostic accuracy, CT-Scan, Malignant, Liver Mass

How to Cite:

Aslam, A. ., Nazir, M., Zain ul Abidin, S. ., Fatima, Z. ., Yousaf Farooq, S. M. ., Zia, S. ., Ahmad, W. ., Adrees, N. ., Naeem, S. ., Imtiaz, A., Fatima, M. ., & Rita, U. . (2022). Diagnostic Accuracy of Ultrasound for Benign and Malignant Hepatic Masses Taking Computed Tomography as Gold Standard: Diagnostic Accuracy of Ultrasound for as Gold Standard. *Pakistan Journal of Health Sciences*, 3(06).
<https://doi.org/10.54393/pjhs.v3i06.269>

***Corresponding Author:**

Arbia Aslam
 University Institute of Radiological Sciences & Medical Imaging Technology, The University of Lahore, Pakistan
arbiaaslam7171p@gmail.com

Received Date: 19th October, 2022

Acceptance Date: 12th November, 2022

Published Date: 30th November, 2022

ABSTRACT

Detection of benign and malignant liver masses is very important for the treatment. **Objectives:** To determine the diagnostic accuracy of ultrasound for hepatic masses taking computed tomography as gold standard **Methods:** It was cross a sectional analytical study to.it involves 266 patients suffering from hepatocellular cell carcinoma age group 45 to 65 years visiting Department of Radiology THQ Hospital Hazro, both genders were included. Consecutive sampling method was used. The collection of data was done through questionnaire and analysis by using SPSS version 25. **Results:** This study enlisted the participation of 261 patients. The average age of all patients was 59.2814 years, with a range of 45 to 65 years. It describes that the total number of true positive disease were 228 which was also detected on ultrasound. However, the occurrence of HCC is highest on CT scan when compared with adenoma and hemangioma. There were 28 patients with multiple lesions, with 71.4 % being malignant and 28.6 % being benign. On the other hand, 22 individuals had a single lesion, of which 36.4% were malignant and 63.6 % were benign (p 0.001). CT had a sensitivity of 96 % to diagnose a malignant lesion, a specificity of 88.4 %, an accuracy of 95.78 %, a positive predictive value of 98.70 %, and a negative predictive value of 73.33 %. **Conclusions:** The results of the present study therefore concluded that CT is a useful modality for the diagnosis of malignant liver masses. Ultrasound had high sensitivity, specificity for the hepatic masses. females were more effected than males. Among hepatic masses, HCC is the commonest.

INTRODUCTION

Liver masses are turning out to be progressively common as imaging modalities like ultrasonography (US), processed tomography (CT), and attractive reverberation imaging (X-ray) become all the more broadly utilized in asymptomatic people, the extraordinary larger part of these sores is recognized unintentionally. For the right determination and treatment of strong liver masses, a total history and actual assessment are fundamental [1]. Utilization of oral contraceptives or anabolic steroids, for instance, might be connected to hepatic adenoma (HA), while liquor utilization and word related openness are connected to angiosarcoma and essential sclerosing cholangitis, and liver accident, Caroli's illness, and choledochal sores are

connected to cholangio-carcinoma [2]. Hepatocellular carcinoma might be shown by a past filled with hepatitis B, C, or cirrhosis of the liver (HCC). Metastatic liver sickness is more probable in the event that you've recently gotten chemotherapy or a growth [3]. In the extraordinary larger part of patients, it is feasible to utilize the benefits of imaging modalities to show up at a precise determination (1.0 cm sores are for the most part harmless) [4]. The presence or nonattendance of cirrhosis in liver masses ought not entirely settle for demonstrative purposes [5]. A hepatic mass in a cirrhotic liver ought to be thought to be HCC except if generally illustrated. In cirrhotic livers, numerous liver masses might be an indication of broad

HCC, high-level dysplastic knobs, or, in very uncommon conditions, hepatic lymphoma. Various hepatic sores are habitually an indication of liver metastases in a sound liver (most regularly from adenocarcinoma of the colon, stomach, lung, or liver)[6]. The liver, which makes around 2 % to 3 % of the general weight, is the greatest organ [7]. The liver is partitioned into two curves, which are generally depicted utilizing two distinct physical classes: morphologic life systems and useful life structures [8]. It is upheld by the ribcage and is held set up by peritoneal reflections known as ligamentous connections in the right upper quadrant of the stomach cavity under the right hemidiaphragm [9]. These connections are internal and associate with the Glisson case, the liver's adaptation of the instinctive peritoneum, regardless of not being genuine ligaments [10]. The use of contrast enhanced computed tomography for this purpose is supported by different previous studies that contrast enhanced computed tomography had an excellent diagnostic modality for the differentiation of different hepatic masses. The point of this study was to figure out the analytic exactness of ultrasound in diagnosis of hepatic masses taking computed tomography as gold standard. And, it will also help the patient to save his pocket rather than visit to other expensive modalities for the purpose of treatment and evaluation of hepatic lesions.

METHODS

This is a cross sectional review used to assess diagnostic accuracy of ultrasound in diagnosis of hepatic masses taking computed tomography as gold standard. This is a cross sectional review study was carried out in the Department of Radiology THQ Hospital Hazro, sample size was Two hundred sixty-six patients of age group 45 to 65 years were included in this study. The inclusion criteria for data collection were patients with HCC of both genders. The exclusion criteria were patient allergic to contrast, pregnant women, any patient with renal problem which was confirmed after creatinine test. Patients was educated about the nature, objective of the review, and composed informed assent was taken, and Institutional Morals Advisory group endorsement was taken ahead of time evaluate diagnostic accuracy of ultrasound in diagnosis of hepatic masses taking 64 -slices computed tomography machine. For the analysis of data, and percentages of qualitative data and quantitative data mean standard deviation was derived. Sensitivity, specificity, PPV and NPV reported to find out the accuracy of ultrasound in hepatic masses. Consecutive sampling method was used. The collection of data were done through questionnaire and analysis by using SPSS version 25.0.

RESULTS

In all, 261 patients were enrolled in this trial. Table 1 the total

number of patients were 261 out of which 124 patients were female and 137 were male. Minimum age limit for female suffering from the disease were 15 while maximum age for female were 95 the mean value was 57.7. SD ratio ± 17.65 . On other hand the minimum age for male were 23 and maximum age was 96 comparatively more than female. The mean value for male were ± 60.8 SD ratio for male were 14.0. However, the SD ratio of female is more as compared to male which shows that the disease rate in female is more as compared to male, Table 1.

Gender	F (N-124)	M (N-137)	Age (N-261)
Minimum	15.00	23.00	15.00
Maximum	95.00	96.00	96.00
Mean+SD	57.71+17.65	60.82+14.06	59.34+15.91

Table 1: Age and Sex distribution of study population(n=261)

The age range for all patients was 45 to 65 years, with a mean of 59.28.14 years. It describes that the total number of true positive disease were 228 which was also detected on ultrasound. However, the occurrence of HCC is highest on CT scan when compared with adenoma and hemangioma. There were 28 patients with multiple lesions, with 71.4 % being malignant and 28.6 % being benign. On the other hand, 22 individuals had a single lesion, of which 36.4% were malignant and 63.6 % were benign (p 0.001). CT had a sensitivity of 96 % to diagnose a malignant lesion, a specificity of 88.4 %, an accuracy of 95.78 %, a positive predictive value of 98.70 %, and a negative predictive value of 73.33 %. Table 2 describes the presence and absences of disease. It describes that the total number of true positive disease were 228 which was also detected on ultrasound. The false negative disease was 22 which was not detected by ultrasound but was present in the patients The table describes 8 false positive results while there were 3 false negative results. The table 2 describes the ratio of disease TP(228)TN(3)and FP(22)FN(8).

Diagnostic Accuracy of Ultrasound

	Disease Present		Disease Absent
True Positive	228	True Negative	3
False Negative	8	False Positive	22
Total	236	Total	25

Table 2: Table shows presence and absence of disease

The frequencies of hepatic masses are shown in Figure 1.

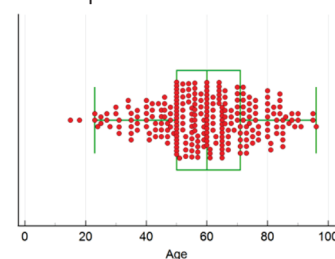


Figure 1: The graph shows the higher frequency of hepatic masses occurring between the age of 45 to 65

Test validity parameters of CT-scan for diagnosis of malignant liver masses.

Sensitivity	96. %	93.4% to 98.5%
Specificity	88.0%	68.7% to 97.4%
AUC	0.92	0.8 to 0.9
Positive Likelihood Ratio	8.05	2.7 to 23.2
Negative Likelihood Ratio	0.03	0.01 to 0.07
Disease Prevalence	90.4%	86.18% to 93.705%
Positive Predictive Value	98. %	96.3% to 99.54%
Negative Predictive Value	73.3%	57.8% to 84.65%
Accuracy	95.7%	92.58% to 97.87%

Table 3: Shows the sensitivity, specificity, prevalence, likelihood ratio and predictive value

CT had a sensitivity of 96 % to diagnose a malignant lesion, a specificity of 88.4 %, an accuracy of 95.78 %, a positive predictive value of 98.70 %, and a negative predictive value of 73.33 %.reported to find out the accuracy of ultrasound in hepatic masses.

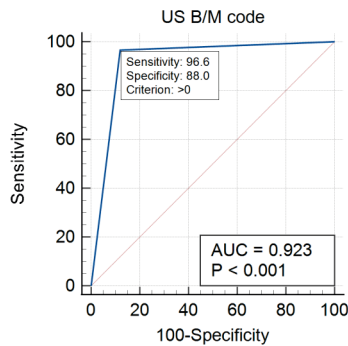


Figure 2: Value of ROC curve: AUC=0.923; p value<0.001

The diagonal segments are produced by ties
The table 4 describes the HCC frequency (90%) higher than hemangioma(6.1%)and adenoma(3.8%).

CT Diagnosis	Yes	Frequency
Adenoma	10	3.8%
HCC	235	90%
emangioma	16	6.1%
Total	261	100%

Table 4: Masses frequency

The ultrasound image of Hepatocellular carcinoma with vascularized hyperechoic mass is shown in figure 3. Figure 4 showed CT scan, result of Hepatocellular carcinoma in the right lobe of liver.

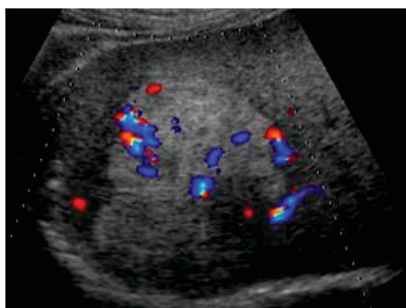


Figure 3: Hepatocellular carcinoma with a vascularized

hyperechoic mass.

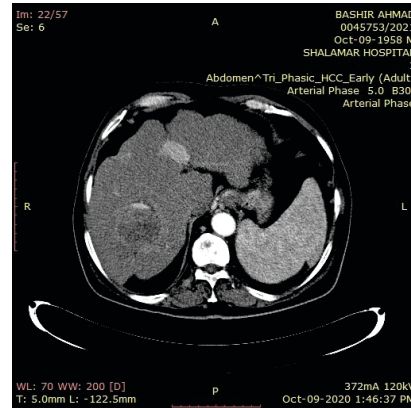


Figure 4: Axial image of CT scan showing HCC in right lobe in VIII segment of liver

DISCUSSION

Liver masses are getting more common among people when diagnosed with the imaging technology especially for the identification of abdominal conditions. Such liver masses can be benign or malignant depending on the diagnoses and identification for providing a specific patient care. Several imaging technologies can be used to identify liver or hepatic masses without any invasive techniques and diagnostic measures. According to study hepatic masses are more likely to be found in male as compared to female. The study showed that male to female ratio was 4:1. Additionally, it also described that HCC was more common between the 40 to 70 years of age [11-14]. According to our study in table 1 the male patients were more likely to have HCC when compared with females. Out of 261 patients 124 patients were female while males were 137. Our study also described that the age frequency was between 45 to 65. According to Jones et al., research described the risk factors and initial liver cancer in a study of more the 5 billion people [15]. The mean SD ratio for men were 11.1 with the age 43.9 years while for females the SD ratio was 12.3 with the age 44.1 years. This shows that females SD ratio was more when compared with male. According to our study the SD ratio for female were 17.6 while for male the SD ratio was 14.0. The results showed that the SD ratio of female with liver mass is more as compared to male. According to another study showed that out of 385 patients, 65 patients were having HCC (6.1%) which were benign and having hemangioma. Schwartz et al., study showed that not all HCC patents are having hemangioma, but it is also not necessary that HCC patients do not have hemangioma [16]. According to our study the frequency of HCC is more as compared to hemangioma and adenoma. The frequency of HCC is 90%, hemangioma is 6.1 and adenoma is 3.8%. Frequency of hemangioma is more than adenoma but less then HCC. Frequency of adenoma is

less comparative to HCC and hemangioma. A sum of 50 CT tests of the hepatobiliary framework were considered. Kang et al., found that CT showed 88% awareness and 98% explicitness in identifying threatening liver masses, as per [17]. Snow et al., done CT, USG, and scintigraphy in 94 patients with clinically thought SOL in the liver and found that CT was the most dependable in tracking down masses and assessing the general level of intrahepatic illness. In this examination, CT was uncovered to have 96% awareness, 86% explicitness, and 95% precision in recognizing threatening liver masses [18]. As per Parveen et al., studied the awareness, particularity, and exactness of CT check for distinguishing SOL. The responsiveness, explicitness, and precision of CT examine for recognizing SOL in liver were 95%, half, and 81%, separately [19]. As per studies, the awareness and explicitness of CT check for estimating the boundaries of harmless and dangerous liver injuries were 94 / 83 / 82 and 55 / 88 / 80, individually. Furthermore, the CT check exactness was 72 / 86 / 81 [20]. In any case, as per our discoveries, the explicitness of CT check for liver masses is 96 / 93 / 98 and the awareness is 88 / 68 / 97 percent. Moreover, CT check exactness for liver masses is 95 / 92 / 97 percent. These findings were nearly identical to those of the current investigation. Based on the current findings and the findings of other researchers, it is clear that CT scans are fitting and exact indicative imaging modalities for the recognizable proof of hepatic masses. This research has certain drawbacks. One of the drawbacks was that there were not enough patients in each of the three types of lesions. This is why we couldn't calculate ultrasound accuracy for each lesion separately.

CONCLUSIONS

The results of the present study therefore concluded that CT is a useful modality for the diagnosis of malignant liver masses. Ultrasound had high sensitivity, specificity for the hepatic masses. females were more effected than males. Among hepatic masses, HCC is the commonest.

Conflict of interest

The authors declare no conflict of interest

Source of Funding

The author(s) received no financial support for the research, authorship and/or publication of this article

REFERENCES

- [1] Giannitrapani L, Soresi M, La Spada E, Cervello M, D'alessandro N, Montalto G. Sex hormones and risk of liver tumor. *Annals of the New York Academy of Sciences*. 2006 Nov; 1089(1):228-36. doi: 10.1196/annals.1386.044
- [2] Dogliotti E. Molecular mechanisms of carcinogenesis by vinyl chloride. *ANNALI-ISTITUTO SUPERIORE DI SANITA*. 2006 Jan; 42(2):163.
- [3] Shaib Y and El-Serag HB. The epidemiology of cholangiocarcinoma. In *Seminars in liver disease* 2004 May (Vol. 24, No. 02, pp. 115-125). Copyright© 2004 by Thieme Medical Publishers, Inc., 333 Seventh Avenue, New York, NY 10001, USA. doi: 10.1055/s-2004-828889
- [4] Coakley FV and Schwartz LH. Imaging of hepatocellular carcinoma: a practical approach. In *Seminars in oncology* 2001 Oct 1 (Vol. 28, No. 5, pp. 460-473). WB Saunders. doi: [10.1016/S0093-7754\(01\)90139-3](https://doi.org/10.1016/S0093-7754(01)90139-3)
- [5] Hussain SM and Semelka RC. Liver masses. *Magnetic Resonance Imaging Clinics* 2005; 13(2):255-75.
- [6] Yamashita Y, Ogata I, Urata J, Takahashi M. Cavernous hemangioma of the liver: pathologic correlation with dynamic CT findings. *Radiology*. 1997 Apr; 203(1):121-5. doi: [10.1148/radiology.203.1.9122378](https://doi.org/10.1148/radiology.203.1.9122378)
- [7] Lizardi-Cervera J, Cuéllar-Gamboa L, Motola-Kuba D. Focal nodular hyperplasia and hepatic adenoma: a review. *Annals of Hepatology*. 2006; 5(3):206-11. doi: 10.1016/s1665-2681(19)32013-7
- [8] Tsao JI, DeSanctis J, Rossi RL, Oberfield RA. Hepatic malignancies. *Surgical Clinics of North America* 2000 Apr; 80(2):603-32. doi: 10.1016/S0039-6109(05)70203-6
- [9] Lim J and Park C. Pathology of cholangiocarcinoma. *Abdominal imaging* 2004 Sep; 29(5):540-7. doi: 10.1007/s00261-004-0187-2
- [10] Kim KW, Kim TK, Han JK, Kim AY, Lee HJ, Park SH, et al., Hepatic hemangiomas: spectrum of US appearances on gray-scale, power Doppler, and contrast-enhanced US. *Korean journal of radiology*. 2000 Dec; 1(4):191-7. doi: 10.3348/kjr.2000.1.4.191
- [11] Borhani AA, Wiant A, Heller MT. Cystic hepatic lesions: a review and an algorithmic approach. *American Journal of Roentgenology*. 2014 Dec; 203(6):1192-204. doi: 10.2214/AJR.13.12386
- [12] Pitchaimuthu M and Duxbury M. Cystic lesions of the liver-A review. *Current problems in surgery*. 2017 Oct; 54(10):514-42. doi: 10.1067/j.cpsurg.2017.09.001
- [13] Noone TC, Semelka RC, Balci NC, Graham ML. Common occurrence of benign liver lesions in patients with newly diagnosed breast cancer investigated by MRI for suspected liver metastases. *Journal of Magnetic Resonance Imaging: An Official Journal of the International Society for Magnetic Resonance in Medicine*. 1999 Aug; 10(2):165-9. doi: 10.1002/(SICI)1522-2586(199908)10:2%3C165::AID-JMRI9%3E3.0.CO;2-Z
- [14] Valls C, Iannaccone R, Alba E, Murakami T, Hori M,

- Passariello R, et al., Fat in the liver: diagnosis and characterization. *European radiology* 2006; 16(10):2292-308. doi: 10.1007/s00330-006-0146-0
- [15] Jones EC, Chezmar JL, Nelson RC, Bernardino ME. The frequency and significance of small (less than or equal to 15 mm) hepatic lesions detected by CT. *AJR. American journal of roentgenology*. 1992 Mar; 158(3):535-9. doi: 10.2214/ajr.158.3.1738990
- [16] Schwartz LH, Gandras EJ, Colangelo SM, Ercolani MC, Panicek DM. Prevalence and importance of small hepatic lesions found at CT in patients with cancer. *Radiology*. 1999 Jan; 210(1):71-4. doi: 10.1148/radiology.210.1.r99ja0371
- [17] Kang BK, Lim JH, Kim SH, Choi D, Lim HK, Lee WJ, et al., Preoperative depiction of hepatocellular carcinoma: ferumoxides-enhanced MR imaging versus triple-phase helical CT. *Radiology*. 2003 Jan; 226(1):79-85. doi: 10.1148/radiol.2261011827
- [18] Snow Jr JH, Goldstein HM, Wallace S. Comparison of scintigraphy, sonography, and computed tomography in the evaluation of hepatic neoplasms. *American Journal of Roentgenology*. 1979 Jun; 132(6):915-8. doi: 10.2214/ajr.132.6.915
- [19] Parveen S. Role of Ultrasound and CT in the Evaluation of Space Occupying Lesions in Liver Prospective Study with Histopathological Correlation. MD Thesis, Bangabandhu Sheikh Mujib Medical University, Dhaka. 2000.
- [20] Marchuk DA. Pathogenesis of hemangioma. *The journal of clinical Investigation*. 2001 Mar 15; 107(6):665-6. doi: 10.1172/JCI12470