



Original Article

Deciphering the Diagnostic Potential of α -Methylacyl CoA Racemase (AMACR) in Prostatic NeoplasmsHuma Abbasi^{1,2}, Ikram Udin Ujjan², Marvi Shaikh^{1*}, Sandhiya Kumari¹, Hadiya Sibghatullah³ and Maleeha Memon¹¹The University of Modern Sciences, Indus Medical College, Tando Muhammad Khan, Pakistan²Liaquat University of Health Sciences, Jamshoro, Pakistan³Department of Pathology, Liaquat University of Medical and Health Sciences, Jamshoro, Pakistan

ARTICLE INFO

Keywords:Prostate Cancer, α -Methylacyl CoA Racemase Expression, Immunohistochemistry, Histological Grading**How to Cite:**Abbasi, H., Ujjan, I. U. ., Shaikh, M., Kumari, S., Sibghatullah, H., & Memon, M. (2025). Deciphering the Diagnostic Potential of α -Methylacyl CoA Racemase (AMACR) in Prostatic Neoplasms: Alpha-Methylacyl CoA Racemase in Prostatic Cancer. *Pakistan Journal of Health Sciences*, 6(4), 66-71. <https://doi.org/10.54393/pjhs.v6i4.2211>***Corresponding Author:**

Marvi Shaikh

The University of Modern Sciences, Indus Medical College, Tando Muhammad Khan, Pakistan
marvishaikh.42@gmail.comReceived date: 25th September, 2025Revised date: 20th March, 2025Acceptance date: 9th April, 2025Published date: 30th April, 2025

ABSTRACT

Prostate cancer is a prevalent malignancy that affects males globally, posing a substantial impact both locally and globally. A critical marker for improving prostatic cancer diagnostic accuracy is α -Methylacyl CoA Racemase (AMACR), an enzyme involved in the metabolism of certain fatty acids and bile acid precursors. **Objective:** To explore the immunohistochemical expression of α -Methylacyl CoA Racemase and assess its association with the histological grading of prostatic adenocarcinoma. **Methods:** This descriptive retrospective cross-sectional study was carried out at Liaquat University of Medical and Health Sciences, Jamshoro between April 2023 to February 2024. Total 71 prostate cancer patients with age range of 45 to 99 years were selected for this study according to the selection criteria. The study used formalin-fixed paraffin-embedded tissue blocks for histopathology to evaluate AMACR expression through immunohistochemistry and the data was analyzed by using the Statistical Package for the Social Sciences (SPSS) for windows. **Results:** The immunohistochemical study revealed that 57.7% of cases showed AMACR expression, with a significant correlation between the expression levels and the tumor's histological grade (P -value < 0.05). **Conclusion:** The findings of this study highlighted AMACR's potential as a diagnostic biomarker for aggressive prostate cancer.

INTRODUCTION

Prostate cancer is a major global health issue, given its high prevalence and the significant role it plays in both illness and death among men. The occurrence of prostate cancer varies greatly across different regions, affected by a combination of genetic, lifestyle influences and environmental. According to the International Agency for Research on Cancer (IARC) in 2020, prostate cancer made up 7.30% of all new cancer diagnoses worldwide, emphasizing its profound impact [1]. In Pakistan, the prevalence of prostate cancer varies between 2.0% to 8.0%, highlighting regional differences that could affect disease management and outcomes [2]. On a diagnostic

level, prostate cancer poses distinct diagnostic challenges [3]. Prostate cancer does not have unique signs and symptoms because most reported symptoms are related to benign prostatic diseases, such as Lower Urinary Tract Symptoms (LUTS). Prostate cancer is often detected and diagnosed using (DRE) digital rectal examination, levels of the Prostate-Specific Antigen (PSA) followed by ultrasound-guided prostate biopsies. Numerous biomarkers specifically for prostate cancer in blood, urine, and tissue have been researched, though they are not frequently used in clinical settings [4, 5]. The Gleason grading system for biopsies is essential for determining the



prognosis of patients with prostate cancer, and it plays a key role in treatment planning [6]. Alpha-Methylacyl-CoA Racemase (AMACR) is an enzyme important for the metabolism of branched-chain fatty acids and serves as a key biomarker in the diagnosis of prostatic adenocarcinoma [7]. Identifying AMACR expression, along with other diagnostic markers, plays a central role in accurate histopathological assessment, which is vital for making an accurate diagnosis and developing effective treatment plans [8, 9]. AMACR is not completely sensitive. Its presence is not only limited to prostate cancer but can also be detected in some other similar types of tumors, which may create certain restrictions in its applicability. As a result, AMACR must be evaluated as a novel marker of prostatic cancer [10]. Through genome-wide scans of families with familial prostate cancer, it has been revealed that the chromosomal region (5p13) where AMACR is located serves as a susceptibility gene for prostate cancer [8, 11]. Prostate cancer is a complex disease, and accurate diagnosis is crucial for appropriate treatment planning and patient management, this study explores epidemiological trends, diagnostic diagnostics and the influence of histopathological findings on prostate cancer care.

Prostate cancer remains a significant diagnostic challenge due to overlapping clinical features with benign prostatic conditions and the limited specificity of conventional diagnostic tools. Although AMACR has emerged as a promising immunohistochemical biomarker, local data evaluating its diagnostic significance in relation to histological grading and Gleason score in Pakistani populations remain scarce. Existing studies have insufficiently explored AMACR's role in differentiating aggressive tumor behavior and improving pathological accuracy. Therefore, this study aimed to assess AMACR expression in prostatic adenocarcinoma and determine its association with histological grade and Gleason scoring to strengthen diagnostic and prognostic evaluation.

METHODS

This Descriptive retrospective cross-sectional study was conducted in the Pathology Department at Liaquat University of Medical and Health Sciences, Jamshoro/Hyderabad from April 2023 to February 2024. Total 71 prostate cancer patients with age range of 45 to 99 years were included, based on a sample size calculation designed to achieve 95% confidence with a 5% margin of error, assuming a 4.8% prevalence rate [3]. Ethical approval for the study was obtained from the Ethical & Review Committee of Liaquat University of Medical Health Sciences (No. LUMHS/REC/-26). Participants who met the inclusion criteria were enrolled, and written informed consent was acquired from each participant before their involvement in the study. Data collection was carried out using a predefined questionnaire. Inclusion criteria for the

study was patients with age range of > 45 years, having ability to understand the questions and willing to participate, encompassed formalin-fixed paraffin-embedded tissue blocks with sufficient material and confirmed diagnoses of prostate adenocarcinoma. Specimens required good histological orientation, identifiable gland formation, and no basal cell layer. Exclusion criteria were inadequate tissue, extensive necrosis, poor fixation, and unwilling participants. Patient identifiers, including name, age, and registration number on the questionnaire and pathology receipt, were cross-verified with the biopsy form and container coding. The biopsy forms were reviewed to gather patient history, clinical findings, radiological findings, intraoperative findings, and relevant investigations. The provisional diagnosis provided by the consultant surgeon was also recorded. Specimens were initially fixed in 10% formalin, processed, and embedded in paraffin. Sections were cut at 3 µm thickness and stained with Hematoxylin and Eosin (HandE) for diagnostic assessment. In this study Dako Flex Detection System has been used for the detection of AMACR Receptor. All of these cases were performed with a negative and positive control on the sample size of 71 cases. Kidney was taken as the positive control for AMACR. The process included sectioning, dewaxing, antigen retrieval, and staining with primary and secondary antibodies. DAB chromogen was used for visualization, followed by counterstaining with Hematoxylin. The expression of AMACR was interpreted by nuclear staining in neoplastic cells. This was further scored for intensity and proportion. This interpretation was done by two pathologists at different times to ensure uniformity in results and to remove any bias. The pathologist examined the prostate to determine the configuration of cancer cells there, and then assigned a grade on a scale from three to five, based on two separate sites. On the other hand, in order to regulate a patient's Gleason score, invasive tissue samples were required.

Gleason Score	Grade Group	Characteristics
6	Grade Group 1	<ul style="list-style-type: none"> Less aggressive Very slow growing Low risk
3 + 4 = 7	Grade Group 2	<ul style="list-style-type: none"> Slightly aggressive Slow growing Low to Intermediate risk
4 + 3 = 7	Grade Group 3	<ul style="list-style-type: none"> Moderately aggressive Fast growing Intermediate to High risk
8	Grade Group 4	<ul style="list-style-type: none"> Aggressive Rapidly growing High risk
9-10	Grade Group 5	<ul style="list-style-type: none"> Highly aggressive Rapidly growing High risk

Figure 1: Gleason scores 6 - 10 alongside their common characteristics for prostate cancer risk [12].

Data analysis was performed using SPSS version 22.0, assessing frequencies, percentages, and associations between AMACR expression and tumor characteristics using the chi-square test, with significance set at $p < 0.05$.

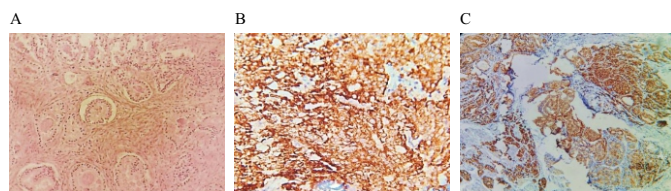


Figure 2: Histopathological and Immunohistochemical Expression of Alpha-Methylacyl CoA Racemase in Prostatic Tissue (A) Normal histological architecture under H&E stain; (B) Diffuse strong positive AMACR expression; (C) Diffuse moderate positive AMACR expression

Figure 2 (A) showed a Hematoxylin and Eosin (HandE) stained section having normal histological architecture. (B) Shows a strong positive expression of Alpha-Methylacyl-CoA Racemase (AMACR), supported by strong staining highlighting the presence of the enzyme in locations thought to be malignant transformation targets. (C) Shows a diffuse moderate positive expression of AMACR, indicating a more distributed but significant presence of this important biomarker over the tissue sample, thereby reflecting different degrees of neoplastic activity. Differentiation relates to how abnormal cancer cells look under a microscope: Well-differentiated adenocarcinoma: Low-grade cancer that tends to grow and spread slowly. Moderately differentiated adenocarcinoma: Intermediate-grade cancer that grows faster than well-differentiated cells. Poorly differentiated adenocarcinoma: High-grade cancer that spreads faster than moderately differentiated cells.

RESULTS

Total 71 patients with prostate cancer were enrolled in the study, with an average age of 66.65 ± 10.34 years, with a minimum age of 45 years and a maximum age of 99 years (Table 1).

Table 1: Descriptive Statistics of Age of Patients (n=71)

Descriptive Statistics	Age (Years)/Mean \pm SD
Mean	66.65 \pm 10.34
Median	68.0 Years
Minimum	45 Years
Maximum	99 Years

Based on the clinical manifestations (Figure 3), it was observed that Nocturia and dribbling were present in 6.2% of the cases. Weight loss was evident in 54.9%, blood in the urine was reported in 9.4% of the patients, dysuria was experienced by 13.8% of the cases and kidney pain was noted in 15.5% of the cases.

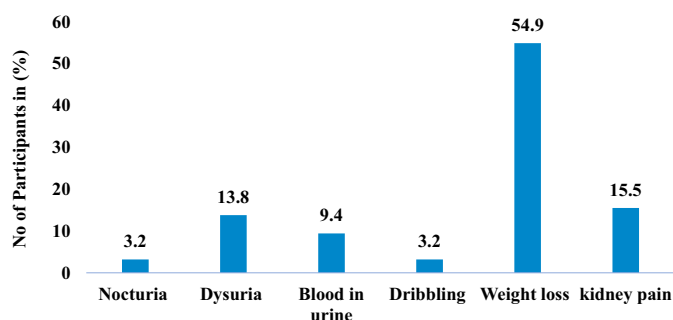


Figure 3: Clinical Presentations of the Patients

Table-2 illustrates that 8.5% of the cases exhibited a favorable familial medical background of the disease. A comprehensive comprehension of the correlation between family history and the susceptibility to prostate cancer stands as a crucial factor in predicting cancer risk. Three grade groups of prostate carcinoma and subtypes were taken in this study. A small proportion, accounting for 2.8% of the cases, exhibited a well differentiated" grade groups, in contrast, a considerable portion, representing 35.2% of the cases, was classified as Moderately differentiated, however, the majority of cases, encompassing 62%, fell into the Poorly differentiated category. A small portion, constituting 2.8% of the cases, were classified as Grade group 1, Grade group 3 accounting for 23.9% of the cases, Grade group 4 encompassing 11.3% of the cases, represents neoplasms of intermediate severity. The majority of cases 62.0% were classified as Grade group 5, indicative of the most severe and highly malignant prostatic neoplasms.

Table 2: Frequencies of Family History of Cancer, Histological Grades, and Grading Groups of Prostatic Neoplasm (n=71)

Variables	Frequency (%)
Family History of Cancer	
Positive	6 (8.50%)
Negative	65 (91.50%)
Histological Grade Groups	
Well Differentiated	2 (2.80%)
Moderately Differentiated	25 (35.20%)
Poorly Differentiated	44 (62.0%)
Grading Groups of Prostatic Neoplasm	
Grade 1	2 (2.80%)
Grade 3	17 (23.90%)
Grade 4	8 (11.30%)
Grade 5	44 (62.0%)

The results of the analysis of AMACR expression in a sample of 71 cases offer a comprehensive overview of the distribution and occurrence of this biomarker within the samples. In the cases under examination, 57.7% displayed a Diffuse Strong Positive expression, while only 2.8% were categorized as Diffuse Weak Positive. A noteworthy 33.8% of the cases showed a diffuse moderate positive expression that was both widespread and diffuse.

Furthermore, 5.6% of the cases exhibited a Focal Weak Positive expression, indicating a relatively lower level of AMACR presence compared to the other categories.

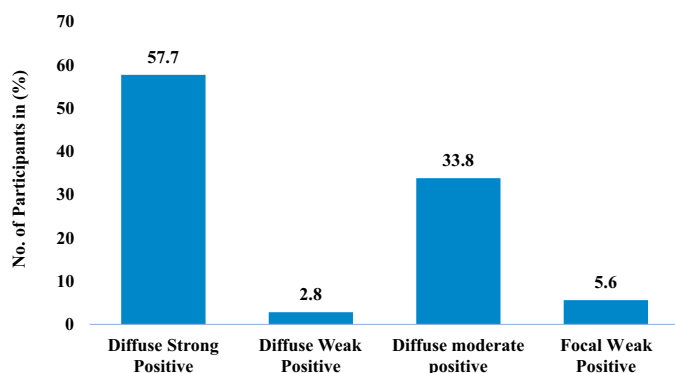


Figure 3: Descriptive Statistics of Expression of AMACR

Table 3: Expression of AMACR according to Tumor Grading

AMACR Score	Grading of Prostatic Adenocarcinoma				p-Value
	Moderately differentiated	Poorly differentiated	Well differentiated	Total	
Diffuse Strong Positive	22	19	0	41	0.001
Diffuse Moderate Positive	0	1	1	2	
Diffuse Weak Positive	1	23	0	24	
Focal Weak Positive	2	1	1	4	
Total	25	44	2	71	

Chi-square test applies, χ^2 test-value 43.095

Table 4 shows the distribution of cases across Gleason grade groups and AMACR Score categories. In Gleason grade group 1, there are no cases with Diffuse Strong Positive, 1 case with Diffuse Moderate Positive, none with Diffuse Weak Positive, and 1 case with Focal Weak Positive, totaling 2 cases. The table also details the data for Gleason grade groups 3, 4, and 5. The p-value of 0.0001 indicates a statistically significant association between Gleason grade groups and AMACR Score.

Table 4: Expression of AMACR according to Gleason Score

Gleason Score	AMACR Score				Total	p-Value
	Diffuse Strong Positive	Diffuse moderate Positive	Diffuse Weak Positive	Focal Weak Positive		
1	0	1	0	1	0.001	
3	15	0	1	1		
4	7	0	0	1		
5	19	1	23	1		
Total	41	2	24	4		

DISCUSSION

Prostate cancer is the most common cancer in men, especially those aged 70 and older [13]. Limited research has explored the link between hereditary and advanced-stage prostate cancer [14]. One study found a connection between prostate cancer and family history, regardless of environmental factors. However, a 2004 study by Sree Kumar A in India reported a younger median age of 59.8 years for prostate cancer [15]. Other studies observed average patient ages of 77.4 years, 71 years, and an age range of 55 to 83 years [16]. A study by Tindall E and colleagues found that common symptoms of prostate cancer include urinary retention, erectile dysfunction, frequent urination, insomnia, and weight loss. Dysuria (7.8%), difficulty urinating (72.3%), and poor urine flow

(1.4%) were the most reported complaints [17]. Another study reported urinary retention, impotence, frequent urination, nocturia, and weight loss in various proportions among 217 patients [18]. In a national study by Khan SA et al., dysuria was the most common symptom, with other patients reporting difficulty urinating, erectile dysfunction, groin pain, and blood in the urine. Symptom variations may be due to environmental and geographical factors [19]. Tumor grade indicates differentiation level. Most cases were poorly differentiated grade 3 (62%), followed by moderately differentiated grade 2 (35.2%), and well-differentiated grade 1 (2.8%). A previous study found 3.8% of prostatic adenocarcinomas were well differentiated, 52.5% were moderately differentiated, and

43.8% were poorly differentiated [20].AMACR staining showed diffuse strong positivity in 57.7% of cases, moderate positivity in 33.8%, weak positivity in 2.8%, and focal positivity in 5.6%. These results are consistent with Vahini Gudeli's study, which found 81% diffuse positivity and 19% focal positivity. Magi-Galluzzi C *et al.*, reported 88% AMACR positivity in 209 prostate biopsy cases, and Hassan Tariq's study found 85% positivity among 80 cases [21, 22]. Overall, 91.2% of cases showed positive AMACR expression, with 8.8% negative. AMACR immunohistochemistry results were positive in 85% of cases, similar to international studies showing 82% and 92% positivity, but higher than the 70.6% found in a Japanese study [23]. In the Pakistani subgroup, results aligned with international findings. The study also examined the impact of Gleason scores on AMACR expression, with positive expression observed in Gleason scores of 3, 4, and 5. Kumar *et al.*, reported no AMACR expression in Gleason score 4, with sensitivity increasing to 94.7% and 100% for scores 8 and 9, respectively. Most cases presented with high-grade cancers[11].

The study was limited by its retrospective cross-sectional design, relatively small sample size, single-center setting, and short study duration, which restricted long-term follow-up and outcome assessment. Additionally, environmental, genetic, and survival-related factors were not evaluated, limiting broader clinical interpretation. Future research should involve larger multicenter prospective studies incorporating long-term patient monitoring, molecular profiling, and survival analysis to further validate AMACR as a reliable prognostic biomarker and enhance personalized management strategies for prostate cancer patients.

CONCLUSIONS

AMACR was found to be effective in diagnosing prostate cancer, particularly in small foci. Its expression is closely linked to tumor grade and Gleason score, showing diffuse positivity in aggressive lesions. This association aids in disease stratification and prognosis, leading to improved outcomes with timely treatment. The study's eleven-month duration limited its scope, preventing patient follow-up. Additionally, environmental and risk factors associated with prostate adenocarcinoma were not assessed, and the relationship between AMACR expression and mortality or morbidity could not be evaluated.

Authors' Contribution

Conceptualization: HA, IUU, MS

Methodology: IUU, MS

Formal analysis: SK, HS, MM, MS

Writing and Drafting: HA, IUU, SK, HS, MM, MS

Review and Editing: HA, IUU, SK, HS, MM, MS

All authors approved the final manuscript and take responsibility for the integrity of the work

Conflicts of Interest

All the authors declare no conflict of interest.

Source of Funding

The author received no financial support for the research, authorship and/or publication of this article.

REFERENCES

- [1] Badar F and Mahmood S. Cancer in Lahore, Pakistan, 2010-2019: an incidence study. *British Medical Journal Open*. 2023 Oct; 11(8): e047049. doi: 10.1136/bmjopen-2020-047049.
- [2] Soerjomataram I and Bray F. Planning for tomorrow: global cancer incidence and the role of prevention 2020-2070. *Nature Reviews Clinical Oncology*. 2021 Oct; 18(10): 663-72. doi: 10.1038/s41571021-00514-z.
- [3] Moradi A, Zamani M, Moudi E. A systematic review and meta-analysis on incidence of prostate cancer in Iran. *Health Promotion Perspectives*. 2019 May; 9(2): 92. doi: 10.15171/hpp.2019.13.
- [4] Esfahani M, Ataei N, Panjehpour M. Biomarkers for evaluation of prostate cancer prognosis. *Asian Pacific Journal of Cancer Prevention*. 2015; 16(7): 2601-11. doi: 10.7314/APJCP.2015.16.7.2601.
- [5] Hasan IA, Gaidan HA, Al-Kaabi MM. Diagnostic value of cytokeratin 34 beta E12 (Ck34βE12) and α-Methylacyl-CoA racemase (AMACR) immunohistochemical expression in prostatic lesions. *Iranian Journal of Pathology*. 2020 May; 15(3): 232. doi: 10.30699/ijp.2020.113544.2229.
- [6] Mohler JL, Antonarakis ES, Armstrong AJ, D'Amico AV, Davis BJ, Dorff T *et al.* Prostate cancer, version 2.2019, NCCN clinical practice guidelines in oncology. *Journal of the National Comprehensive Cancer Network*. 2019 May; 17(5): 479-505. doi: 10.6004/jnccn.2019.0023.
- [7] Luo J, Zha S, Gage WR, Dunn TA, Hicks JL, Bennett CJ *et al.* α-Methylacyl-CoA racemase: a new molecular marker for prostate cancer. *Cancer Research*. 2002 Apr; 62(8): 2220-6.
- [8] Fu P, Bu C, Cui B, Li N, Wu J. Screening of differentially expressed genes and identification of AMACR as a prognostic marker in prostate cancer. *Andrologia*. 2021 Jul; 53(6): e14067. doi: 10.1111/and.14067.
- [9] Etheridge T, Straus J, Ritter MA, Jarrard DF, Huang W. Semen AMACR protein as a novel method for detecting prostate cancer. *In Urologic Oncology: Seminars and Original Investigations* 2018 Dec; 36(12): 532-e1. doi: 10.1016/j.urolonc.2018.09.010.
- [10] Jiang N, Zhu S, Chen J, Niu Y, Zhou L. A-methylacyl-CoA racemase (AMACR) and prostate-cancer risk: a meta-analysis of 4,385 participants. *PLOS One*. 2013 Oct; 8(10): e74386. doi: 10.1371/journal.pone.0074386.
- [11] Kumar S, Bukhari U, Sikandar B, George A, Memon Y, Khan N *et al.* Sensitivity of Alpha-Methylacyl-CoA Racemase (AMACR) Staining in Prostatic

- Adenocarcinoma. *Journal of Liaquat University of Medical & Health Sciences*. 2020 Oct; 19(4).
- [12] Virgo KS, Rumble RB, Talcott J. Initial management of noncastrate advanced, recurrent, or metastatic prostate cancer: ASCO guideline update. *Journal of Clinical Oncology*. 2023 Jul; 41(20): 3652-6. doi: 10.1200/JCO.23.00155.
- [13] Boyle HJ, Alibhai S, Decoster L, Efsthathiou E, Fizazi K, Mottet N et al. Updated recommendations of the International Society of Geriatric Oncology on prostate cancer management in older patients. *European Journal of Cancer*. 2019 Jul; 116: 116-36. doi: 10.1016/j.ejca.2019.04.031.
- [14] Bratt O, Drevin L, Akre O, Garmo H, Stattin P. Family history and probability of prostate cancer, differentiated by risk category: a nationwide population-based study. *Journal of the National Cancer Institute*. 2016 Oct; 108(10): djw110. doi: 10.1093/jnci/djw110.
- [15] Sreekumar A, Laxman B, Rhodes DR, Bhagavathula S, Harwood J, Giacherio D et al. Humoral immune response to α -methylacyl-CoA racemase and prostate cancer. *Journal of the National Cancer Institute*. 2004 Jun; 96(11): 834-43. doi: 10.1093/jnci/djh145.
- [16] Aldaoud N, Graboski-Bauer A, Abdo N, Al Bashir S, Oweis AO, Ebwaini H et al. ERG expression in prostate cancer biopsies with and without high-grade prostatic intraepithelial neoplasia: a study in Jordanian Arab patients. *Research and Reports in Urology*. 2019 May: 149-55. doi: 10.2147/RRU.S207843.
- [17] Tindall EA, Monare LR, Petersen DC, Van Zyl S, Hardie RA, Segone AM et al. Clinical presentation of prostate cancer in black South Africans. *The Prostate*. 2014 Jun; 74(8): 880-91. doi: 10.1002/pros.22806.
- [18] Yee CH. An Investigation of Lower Urinary Tract Symptoms as the Outcome of Factors beyond Just an Enlarged Prostate (Doctoral dissertation, The Chinese University of Hong Kong (Hong Kong)).
- [19] Khan SA. Prostate Cancer in Patients Presenting With Lower Urinary Tract Symptoms. *Journal of Surgery Pakistan*. 2019 Oct; 24(3): 148-52.
- [20] Bangash SA. Expression of Alpha Methyl Acyl-Coa Racemase (AMACR) Immunohistochemistry in Carcinoma Prostate in Tertiary Care Hospital. 2022 Jan; 16(1): 1413. doi: 10.53350/pjmhs221611413.
- [21] Galluzzi C, Luo J, Isaacs WB, Hicks JL, De Marzo AM, Epstein JI. α -Methylacyl-CoA racemase: a variably sensitive immunohistochemical marker for the diagnosis of small prostate cancer foci on needle biopsy. *The American Journal of Surgical Pathology*. 2003 Aug; 27(8): 1128-33. doi: 10.1097/00000478-200308000-00010.
- [22] Akhtar S, Hassan F, Ahmad S, El-Affendi MA, Khan MI. The prevalence of prostate cancer in Pakistan: A systematic review and meta-analysis. *Heliyon*. 2023 Oct; 9(10). doi: 10.1016/j.heliyon.2023.e20350.
- [23] Nomani BH, Alamgir M, Wasti H, Nadeem S. Immunohistochemical expression of Alpha-Methylacyl-CoA Racemase in Benign Prostate Hyperplasia and Adenocarcinoma Prostate. *Isra Medical Journal*. 2021 Jan; 13: 15-9.