



## Original Article

## The Risks of Early Complications from Level II Axillary Clearance in Modified Radical Mastectomy

Tariq Jamil<sup>1</sup>, Javed Mirdad Tarar<sup>2</sup>, Ferwa Nasir<sup>3</sup>, Muhammad Maqsood Zahid<sup>4</sup> and Akhtar Ali<sup>5</sup><sup>1</sup>Department of General Surgery, Bakhtawar Amin Medical and Dental College, Multan, Pakistan<sup>2</sup>Department of Thoracic Surgery, Bakhtawar Amin Medical and Dental College, Multan, Pakistan<sup>3</sup>Department of Oncology, Bakhtawar Amin Medical and Dental College, Multan, Pakistan<sup>4</sup>Aziz Bhatti Shaheed Hospital, Gujrat, Pakistan<sup>5</sup>Department of Surgery, Sialkot Medical College, Sialkot, Pakistan

## ARTICLE INFO

**Keywords:**

Breast Cancer, Radical Mastectomy, Level II Axillary, Seroma

**How to Cite:**

Jamil, T., Tarar, J. M., Nasir, F., Zahid, M. M., & Ali, A. (2024). The Risks of Early Complications from Level II Axillary Clearance in Modified Radical Mastectomy: Level II Axillary Clearance in Modified Radical Mastectomy. *Pakistan Journal of Health Sciences*, 5(07). <https://doi.org/10.54393/pjhs.v5i07.1909>

**\*Corresponding Author:**

Tariq Jamil  
 Department of General Surgery, Bakhtawar Amin Medical and Dental College, Multan, Pakistan  
 drtariqch@hotmail.com

Received Date: 11<sup>th</sup> June, 2024Acceptance Date: 26<sup>th</sup> July, 2024Published Date: 31<sup>st</sup> July, 2024

## ABSTRACT

The second leading cause of cancer fatalities in women is breast cancer. Complete breast tissue removal and axillary lymph node removal are performed in a modified radical mastectomy. Seroma is the most frequent surgical complication. Due to inadequate data, our study would give significant data on this issue and wound infection. **Objective:** To determine the most prevalent early difficulties observed by early breast cancer patients after a modified radical mastectomy with axillary clearing. **Methods:** This descriptive research included 135 women who had a modified radical mastectomy with level II axillary clearance for early-stage breast cancer. After surgery, we monitored these patients in the Breast Clinic for up to a month for any issues. This data set used SPSS version 24.0. **Results:** The patients' average age was  $50.12 \pm 7.44$  years. Seroma development was the most prevalent consequence found in 47 (34.8%) patients, while 35 patients (24.9%) experienced edema of the arm. In 15 patients (11.1%) wound infection was noted, 12 patients (8.9%) had paresthesia, 8 patients (5.9%) had a hemorrhage, in 7 patients (5.2%) hematoma was noted, and 7 patients (5.2%) developed skin flap necrosis. In 5 patients (3.7%), paralysis of the serratus anterior and Latissimus Dorsi muscles was detected. **Conclusions:** A modified radical mastectomy can cause complications like seroma formation, wound infection, arm edema, hemorrhage, skin flap necrosis, serratus anterior muscle paralysis, intercostobrachial nerve paresthesia, and axillary dissection. Correct postoperative care can detect these issues.

## INTRODUCTION

Cancer of the breast affects 1 in 5 women. It is the second leading cause of death for female globally [1, 2]. These days, breast cancer treatment requires a multi-specialty group. Modified radical mastectomy, plain mastectomy, and conservative breast surgery are a few surgical options for breast cancer therapy [3]. Breast cancer patients often have axillary dissection and wide local excision in addition to modified radical mastectomy. Common early problems after breast surgery include seroma formation, skin flap necrosis, wound infection, and a high rate of morbidity and mortality. An infection in the wound is considered postoperative wound infection if it appears within one

month after surgery [4]. Since it was initially documented as a component of radical mastectomy, axillary dissection for breast cancer has persisted with radical mastectomy modifications [5]. From the medial boundary of the axilla to the second to sixth ribs along the chest wall, all external mammary nodes were carefully removed as part of this framework, which also required the removal of lymph nodes at three levels. A transection of the pectoralis minor muscle was performed to access the level III apical nodes [6]. This muscle was originally attached to the coracoid process. The sternal part of the pectoralis major was also laterally removed to open up more space in the axillary

area. In the next steps, the muscle was rebuilt. As more information about the location of nodal micrometastases became available and breast-conserving treatments gained popularity, the scope of elective axillary dissection was often modified [7]. Little more than one percent of cases had level III micro-metastases in the absence of level I or II metastases. The prevalence of solo metastases to level II was found to be less than 2% in certain research, whereas over 20% of "skip" metastases were reported in other publications [8, 9]. As a result, most publications now show level I and II dissection as the anatomic extent of axillary lymphadenectomy, while the pectoralis minor is preserved [10]. From what we can tell from their medical records, 20% of patients suffered seroma development, 18% wound infections, and 2% skin flap necrosis [11]. A 100% seroma formation rate, a 6-14% wound infection rate, and an 8-60% necrosis rate have been reported by various sources. These issues are not life-threatening because patients fully recover with the right administration of antibiotics, drainage, and flap implantation and removal. The leading complication following breast cancer surgery, seroma, has an unknown origin. Seromas occurred in 15.8% of patients overall, 19.9% of patients undergoing MRM, and 9.2% of patients undergoing breast-conserving surgery (p=0.01)[10]. In cases of breast cancer, seroma formation is the most common wound complication following axillary lymph node dissection and modified radical mastectomy. About 50% of patients who get a mastectomy will experience this [12].

A modified radical mastectomy with axillary clearance at level II was performed on patients with breast cancer.

This study aimed to determine the frequency of early post-procedure complications.

## METHODS

A descriptive study was conducted at the Department of Surgery, Bakhtawar Amin Trust Teaching Hospital, Multan after getting approval from the ethical review board with reference number (2767/MD/BATTH). The duration was 14 months from February 2023 to April 2024, with the established diagnosis of carcinoma of the breast and underwent modified radical mastectomy with axillary clearance. Exclusion criteria included patients who had a history of palliative mastectomy (LABC with metastatic lesion) or who had undergone a modified radical mastectomy operation. Because the needed sample size was 135 patients, the estimation of the sample size was based on the prevalence of 18%, the margin of error was 10%, and the confidence interval was 95%. The non-probability purposive sampling approach was modified to fit the situation. Each patient underwent a thorough clinical examination, baseline testing, and an informed consent process before a thorough medical history was obtained. For individuals who may have distant metastasis,

it was recommended to undergo bone scans and abdominal ultrasounds. Both FNAC and open biopsy were used to confirm the diagnosis of breast cancer in individuals. All of these patients were observed for postoperative complications for one month at the Breast Clinic on an outpatient basis after undergoing modified radical mastectomy with axillary clearance. We recorded all of the following findings in a specially constructed proforma. All patients had their clinical and demographic details recorded. A confirmation of breast cancer was achieved using an open biopsy, which also served to assign a staging system. When doing MRM, standard surgical procedures were adhered to. Notable outcomes included early problems, comorbidities, and risk factors. Complications that occurred within 30 days after MRM were considered to be early complications. "Statistical Package for the Social Sciences (SPSS)" version 24.0 was used for data analysis. While quantitative data were shown with means and standard deviations (SDs), qualitative variables were indicated with frequencies and percentages. The association between the research variables was determined using Pearson correlation, with a significance level of  $p < 0.05$  being deemed statistically significant.

## RESULTS

The patient's average age was  $50.12 \pm 7.44$  years. 108 (80%) of the patients were married and the mean duration of marriage was  $25.7 \pm 4.26$  years. 55 (40.7%) cases were educated and 80 (59.3%) cases were non-educated. Most cases were from urban areas. Family history of disease was found in 37 (27.4%) cases. Frequency of breastfeeding cases was 73 (54.1%) (Table 1).

**Table 1:** Characteristics of the Cases

Variables	Frequency/Percentage (135)
Mean Age (Years)	50.12
Mean Duration of Marriage (Years)	25.7
<b>Marital Status</b>	
Yes	108 (80%)
No	27 (20%)
<b>Education Status</b>	
Yes	80 (59.3%)
No	55 (40.7%)
<b>Residency</b>	
Rural	60 (44.4%)
Urban	75 (55.6%)
<b>Family History of Disease</b>	
Yes	37 (27.4%)
No	98 (62.6%)
<b>Breast Feeding</b>	
Yes	73 (54.1%)
No	62 (45.9%)

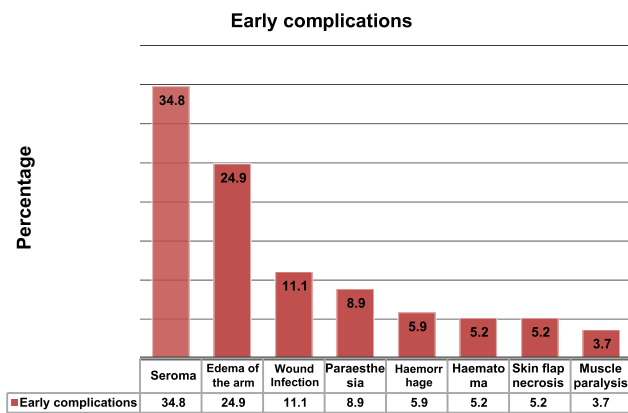
The most common comorbidity was hypertension (HTN), diabetes mellitus (DM), obesity, and smoking. There were 63 (46.7%) patients had tumor stage II, 52 (38.5%) cases had

tumor stage III, and 20 (14.8%) cases had stage I cancer (Table 2).

**Table 2:** Comorbidities and Stages of Cancer Among all Cases

Variables	Frequency/Percentage (135)
<b>Comorbidities</b>	
HTN	48 (35.6%)
DM	40 (29.6%)
Obesity	18 (13.3%)
Smoking	29 (21.5%)
<b>Stage of Tumor</b>	
I	20 (14.8%)
II	63 (46.7%)
III	52 (38.5%)

Seroma development was the most prevalent consequence found in 47 (34.8%) patients, while 35 patients (24.9%) experienced edema of the arm. In 15 patients (11.1%) wound infection was noted, 12 patients (8.9%) had paresthesia, 8 patients (5.9%) had a hemorrhage, in 7 patients (5.2%) hematoma was noted, and 7 patients (5.2%) developed skin flap necrosis. In 5 individuals (3.7%), paralysis of the serratus anterior and latissimus dorsi muscles was detected (Figure 1).



**Figure 1:** Modified Radical Mastectomy. Potential Risks and Consequences in Patients with Level II Axillary Clearance

In terms of p-values, the association between the most frequently occurring post-surgical complications and the accompanying comorbidities is being evaluated (Table 3).

**Table 3:** Associated Risk Variables and Post-Mastectomy Problems Had a p-Value Less Than 0.05

Variables	Wound Infections	Seroma Formation
<b>Comorbidities</b>		
Stage of Cancer	0.579	0.416
HTN	0.512	0.004*
DM	0.612	0.001*
Obesity	0.298	0.003*

## DISCUSSION

Nowadays, a multidisciplinary strategy is used to manage breast cancer. The first presenting stage of the disease,

the patient's age, the patient's preference, and the surgeon's option all play a role in determining the surgical treatment for breast cancers. The technique with the highest frequency of occurrence is modified radical mastectomy with axillary clearance [13]. Significant morbidity and death are inherent to all surgical procedures. Consistent with Moo et al., 47 individuals (34.8%) experienced seroma development as a complication. According to the research, seroma production rates range from 4.2% to 89% in axillae that have not been drained, and they reach 53% in drained axillae. One way to avoid this problem is to put a suction drain deep into the axilla, where the mastectomy flaps [14]. Seroma is more common in older patients, those with larger breasts, those with axillary lymph nodes, those who have had a prior surgical biopsy, those with hypertension, and those who used heparin [15]. Similarly, this study found that seroma more commonly occurred in elderly patients, those with hypertension, and those whose axillary lymph nodes tested positive for metastasis. After multiple aspirations, every single one of our patients made a full recovery. Prior reports indicated instances of fibrous encapsulated seroma following radical mastectomy, which ultimately necessitated surgical removal due to its resistance to conservative treatment. Nonetheless, we could not find any evidence of seroma development in our research. Therefore, seroma is a "necessary evil" that will affect a predicted percentage of people in an unpredictable way [16]. By performing a modified radical mastectomy, the surgeon removes breast tissue while also surgically clearing the axilla. So, for these people, axillary radiation following a mastectomy is not required. Although the extent can vary, most surgeons do level 1 and level 2 axillary clearance. Level 1 clearance requires the removal of lymph nodes situated laterally to the lateral border of the Pectoralis minor muscle. Lymph nodes between the medial and lateral borders of the Pectoralis minor muscle and inter-pectoral lymph nodes need to be excised for level 2 clearance. In most cases, a nosocomial or hospital-acquired bacteria is to blame for the wound infection. Smoking, fluid accumulation, and wound separation are the causes of wound infections. Of the two organisms that caused the disease, Staphylococcus aureus was far more frequent than pseudomonas aeruginosa [17]. In a previous research, wound infections occurred in 3.6% of patients in a combination of a sterile dressing changed daily and antibiotics prescribed based on the patient's culture and sensitivity results used to treat wound infections. It is reported that approximately 50% of individuals experience early arm edema following axillary dissection [18]. The majority get edema, however it is usually so mild that people do not even notice it. The likelihood of lymphedema increases with both the pre-and post-operative body mass index being higher. This issue was noted in 24.9% of the

cases. Lymphedema was observed in 28.8% and 27.8% of participants in the other two investigations, respectively [19, 20]. Extensive mobilization was associated with 5.2% of cases of skin flap necrosis. After having the skin margins removed, another patient who had diabetes, hypertension, and a stroke resolved the flap necrosis. Repetitive excision of skin was necessary in one patient with comorbid. The most likely theory is that successful wound healing necessitates the activation of immune cells, the production of proteins, and a healthy nutritional state. During a mastectomy, a patient with locally advanced breast cancer who was experiencing bleeding, ulceration, and a low hemoglobin level had a big defect covered with a rotational skin flap. Half of the flap had necrosis. Reducing the amount of cautery used, injecting adrenaline-containing solutions into subcutaneous tissue, using suction drains routinely, and applying pressure garments can all reduce the incidence of skin flap problems following radical breast cancer surgery [21, 22]. There is substantial psychological morbidity in the years after a mastectomy for breast cancer, according to studies. Possible causes include a decline in her health, sense of self-worth, femininity, or purpose in life [23]. Acute depression was also experienced by two of our patients following surgery. However, after much deliberation and consultation, antipsychotic medication was ultimately chosen.

## CONCLUSIONS

Early warning signs of complications from a modified radical mastectomy with axillary dissection include seroma formation, wound infection, edema of the arm, paresthesia from the involvement of the intercosto-brachial nerve, hemorrhage, necrosis of the skin flap, and paralysis of the serratus anterior muscles. These issues can be identified with correct postoperative care.

## Authors Contribution

Conceptualization: TJ

Methodology: TJ

Formal analysis: MMZ, AA

Writing-review and editing: JMT, FN

All authors have read and agreed to the published version of the manuscript.

## Conflicts of Interest

The authors declare no conflict of interest.

## Source of Funding

The authors received no financial support for the research, authorship and/or publication of this article.

## REFERENCES

[1] Cifu G and Arem H. Adherence to lifestyle-related cancer prevention guidelines and breast cancer

incidence and mortality. *Annals of Epidemiology*. 2018 Nov; 28(11): 767-73. doi: 10.1016/j.annepidem.2018.09.002.

- [2] Begum N. Breast Cancer in Pakistan: A Looming Epidemic. *Journal of College of Physicians and Surgeons Pakistan*. 2018 Feb; 28(2): 87-8. doi: 10.29271/jcpsp.2018.02.87.
- [3] Rizvi FH, Khan MK, Almas T, Ullah M, Shafi A, Murad MF et al. Early postoperative outcomes of breast cancer surgery in a developing country. *Cureus*. 2020 Aug; 12(8). doi: 10.7759/cureus.9941.
- [4] Chandrakar N and Shinde RK. Study the early complications of modified radical mastectomy performed. *International Surgery Journal*. 2019; 6(1): 239-43. doi: 10.18203/2349-2902.isj20185480.
- [5] Agarwal N and Agarwal S. Assessment of Risks and Complications, Associated with the Breast Cancer Surgery with Axillary Dissection. *International Journal of Health Sciences*. 2022; 6(S2): 3219-27. doi: 10.53730/ijhs.v6nS2.5801.
- [6] Alturky B, Alotaibi AH, Alghamdi AS, Habibi MA, Ibrahim AA, Alnahwi AH. Mastectomy for Women with Breast Cancer, Types and Considerations. *EC Microbiology*. 2019; 15: 1-0.
- [7] Elhaj AM, Abdalsalam AI, Abuidris AO, Eltayeb AA. Overall survival of female with breast cancer in the National Cancer Institute, University of Gezira, Sudan. *Sudan Medical Monitor*. 2015 Jan; 10(1): 1. doi: 10.4103/1858-5000.157499.
- [8] Mariani-Costantini R, Elhassan MM, Aceto GM, Mohamedani AA, Awadelkarim KD. Epidemiology, pathology, management and open challenges of breast cancer in central Sudan: A prototypical limited resource African setting. *Breast Cancer-From Biology to Medicine*. 2017 Apr; 2(1): 3-14. doi: 10.5772/67175.
- [9] Taskindoust M, Thomas SM, Sammons SL, Fayanju OM, DiLalla G, Hwang ES, Pi et al. Survival outcomes among patients with metastatic breast cancer: review of 47,000 patients. *Annals of Surgical Oncology*. 2021 Nov; 28(12): 7441-9. doi: 10.1245/s10434-021-10227-3.
- [10] Mariani-Costantini R, Elhassan MM, Aceto GM, Mohamedani AA, Awadelkarim KD. Epidemiology, pathology, management and open challenges of breast cancer in central Sudan: A prototypical limited resource African setting. *Breast Cancer-From Biology to Medicine*. 2017 Apr; 2(1): 3-14. doi: 10.5772/67175.
- [11] Elhaj AM, Abdalsalam AI, Abuidris AO, Eltayeb AA. Overall survival of female with breast cancer in the National Cancer Institute, University of Gezira, Sudan. *Sudan Medical Monitor*. 2015 Jan; 10(1): 1. doi:



- 10.4103/1858-5000.157499.
- [12] Isozaki H, Yamamoto Y, Murakami S, Matsumoto S, Takama T. Impact of the surgical modality for axillary lymph node dissection on postoperative drainage and seroma formation after total mastectomy. *Patient Safety in Surgery*. 2019 Dec; 13: 1-9. doi: 10.1186/s13037-019-0199-z.
- [13] Harbeck N, Penault-Llorca F, Cortes J, Gnant M, Houssami N, Poortmans P et al. Cardoso. Breast cancer. *Nature Reviews Disease Primers*. 2019; 5: 66. doi: 10.1038/s41572-019-0111-2.
- [14] Moo TA, Sanford R, Dang C, Morrow M. Overview of breast cancer therapy. *PET Clinics*. 2018 Jul; 13(3): 339-54. doi: 10.1016/j.cpet.2018.02.006.
- [15] Al Awayshih MM, Nofal MN, Yousef AJ. Modified radical mastectomy for male breast cancer. *The American Journal of Case Reports*. 2019; 20: 1336. doi: 10.12659/AJCR.916947.
- [16] Stanczyk M, Grala B, Zwierowicz T, Maruszynski M. Surgical resection for persistent seroma, following modified radical mastectomy. *World Journal of Surgical Oncology*. 2007 Dec; 5: 1-4. doi: 10.1186/1477-7819-5-104.
- [17] Al-Hilli Z and Wilkerson A. Breast surgery: management of postoperative complications following operations for breast cancer. *Surgical Clinics*. 2021 Oct; 101(5): 845-63. doi: 10.1016/j.suc.2021.06.014.
- [18] Melwani R, Malik SJ, Shakeel S, Zafar S, Khoso MY, Ali SN. Frequency of early post operative complications of modified radical mastectomy within period of four weeks. *International Journal of Research in Medical Sciences*. 2020 Apr; 8(5): 1838. doi: 10.18203/2320-6012.ijrms20201938.
- [19] Jalaj A, Ojha A, Sharma K, Gupta A. Factors Affecting Seroma Formation after Modified Radical Mastectomy in Patients of Carcinoma Breast: A Prospective Study. *IJSS Journal of Surgery*. 2016; 2(1):01-05.
- [20] Vishwakarma M and Sahani IS. Comparative study of complications of modified radical mastectomy and breast conservation therapy in early invasive breast cancer. *International Journal of Surgery*. 2019; 3(1): 1-3. doi: 10.33545/surgery.2019.v3.i1a.01.
- [21] Tran CL, Langer S, Broderick-Villa G, DiFronzo LA. Does reoperation predispose to postoperative wound infection in women undergoing operation for breast cancer?. *The American Surgeon*. 2003 Oct; 69(10): 852-6. doi: 10.1177/000313480306901007.
- [22] Tan RZ, Yong B, Aloweni FA, Lopez V. Factors associated with postsurgical wound infections among breast cancer patients: a retrospective case-control record review. *International Wound Journal*. 2020 Oct; 17(5): 1444-52. doi: 10.1111/iwj.13421.
- [23] Agresti R, Triulzi T, Sasso M, Ghirelli C, Aiello P, Rybinska I et al. Wound healing fluid reflects the inflammatory nature and aggressiveness of breast tumors. *Cells*. 2019 Feb; 8(2): 181. doi: 10.3390/cells8020181.