



Original Article

Frequency of Thyrotoxicosis in Patients Presenting with Unilateral Proptosis in District Headquarters Teaching Hospital D.I.Khan

Salman Khan¹, Naseeb-ur-Rehman², Abdur-Rehman¹, Muhammad Zubair¹ and Rida Naz³¹Medical Unit, District Headquarters Teaching Hospital, Gomal Medical College, Dera Ismail Khan, Pakistan²Khalifa Gul Nawaz Teaching Hospital, Bannu, Pakistan³Regional Blood Centre, Dera Ismail Khan, Pakistan

ARTICLE INFO

Keywords:

Unilateral Proptosis, Thyrotoxicosis, Retrobulbar Tumor, Cavernous Sinus Thrombosis, Idiopathic Proptosis

How to Cite:

Khan, S., Rehman, N. ur, Rehman, A., Zubair, M., & Naz, R. (2024). Frequency of Thyrotoxicosis in Patients Presenting with Unilateral Proptosis in District Headquarters Teaching Hospital D.I.Khan: Thyrotoxicosis with Unilateral Proptosis in Patients. *Pakistan Journal of Health Sciences*, 5(06). <https://doi.org/10.54393/pjhs.v5i06.1673>

*Corresponding Author:

Salman Khan
Medical Unit, District Headquarters Teaching Hospital, Gomal Medical College, Dera Ismail Khan, Pakistan
salmankhn663@gmail.com

Received Date: 10th May, 2024Acceptance Date: 25th June, 2024Published Date: 30th June, 2024

ABSTRACT

Thyrotoxicosis is a medical disorder marked by retraction of the eyelids, resulting in a wide-eyed or gazing appearance. This syndrome can occur in patients with any form of hyperthyroidism as a result of increased activity of the sympathetic nervous system. **Objectives:** To investigate the prevalence of thyrotoxicosis and factors contributing to unilateral proptosis, with a specific focus on early diagnosis and prompt treatment. **Methods:** A cross-sectional study was conducted from January 2023 to January 2024 and categorical variables were presented with the frequency and percentage. The study had a total of 62 patients who exhibited unilateral proptosis. The clinical examinations involved a comprehensive collection of medical history, examination of eyes, analysis of blood samples, evaluation of thyroid function, and utilization of advanced imaging techniques. The associations between thyrotoxicosis and demographic variables were evaluated using chi-square tests. Data were entered and analyzed on SPSS version 26. **Results:** The mean age of participants was 27.84 ± 6.8 years and female comprised 54.8% of the total. It was observed that female had a greater incidence rate (73.5%) compared to male (53.6%) ($p > 0.05$). Additional findings included retrobulbar tumors (16.1%), cavernous sinus thrombosis (12.9%), and idiopathic proptosis (6.5%). The prevalence of thyrotoxicosis was highest among individuals aged 15-30 ($p < 0.05$). The most common symptom linked with thyrotoxicosis was diplopia (33.9%) ($p < 0.05$). **Conclusions:** Thyrotoxicosis has a major role in causing unilateral proptosis, especially in female and younger persons. Being female and experiencing pain may serve as predictors for thyrotoxicosis.

INTRODUCTION

Thyroid Eye illness (TED), commonly referred to as Graves' Ophthalmopathy, is acknowledged as the most common non-thyroidal symptom of Graves' illness [1, 2]. This condition is mainly characterized by the enlargement of the tissues around the eye socket, which includes the expansion of connective and fatty tissues, as well as the growth of extraocular muscles in the spaces between these tissues [3]. These alterations take place inside the limited area of the bony orbit, frequently causing an immunological response that progresses autonomously,

culminating in tissue hypoxia, damage caused by oxygen free radicals and remodeling of fibrous tissue [4-6]. TED often advances through two stages: an initial phase of active inflammation that normally lasts between 6 to 24 months (sometimes longer), followed by a static phase [7]. Exophthalmos, also known as proptosis, is a prominent symptom that can be noticed in 20-30% of people with Graves' disease and up to 40-70% of patients with TED. Pure unilateral ophthalmopathy, where only one eye is damaged, is a rare occurrence, accounting for about 5-11%

of cases [8-10]. The occurrence of TED, specifically exophthalmos, differs among different populations. European people bear significantly high prevalence of Graves' Ophthalmopathy compared to Asians. The rate among Europeans is 42%, whereas among Asians is 7.7% [11, 12]. Moreover, Europeans are 6.4 times more prone to develop the Graves' Ophthalmopathy than Asians [11]. TED is a primary reason for both one-sided and two-sided bulging of eyes, impacting about half of individuals with Graves' disease. Approximately 5% of these patients have potential to develop severe dysthyroid optic neuropathy [13]. Additional possible factors contributing to proptosis include orbital cellulitis, mucormycosis, retroorbital tumors and cavernous sinus thrombosis [14]. The cure for TED involves utilizing immunosuppressive drugs when the disease is active and surgical procedures when disease is quiescent. For certain patients, rehabilitative surgical operations including orbital decompression and eyelid surgery is required when the disease becomes stable [15]. The objective of the study was to evaluate the frequency of thyrotoxicosis and other factors contributing to unilateral proptosis, specifically focusing on treatable underlying causes for improving the identification and treatment of unilateral proptosis caused by thyrotoxicosis.

METHODS

A cross-sectional investigation was conducted at the Department of Ophthalmology, District Headquarters Teaching Hospital, Dera Ismail Khan, from January 2023 to January 2024, to evaluate the frequency of thyrotoxicosis and other potential reasons for unilateral proptosis. Prior to their involvement, informed consent was acquired from each patient. The study adhered to the ethical principles specified in the Declaration of Helsinki and obtained permission from Gomal Medical College, Dera Ismail Khan, Pakistan (IRB-273/GJMS/JC, Dated; December 26, 2022). The study included 62 participants having unilateral proptosis. The inclusion criteria comprised the patients exhibiting unilateral proptosis caused by orbital causes. The exclusion criteria comprised unilateral ocular disorders, such as extreme myopia or congenital glaucoma. Each participant underwent a detailed medical history assessment, which included gathering information about the length of the disease, the way it started and course of symptoms over time. In addition any accompanying symptoms such as diplopia, fever, discomfort and visual loss were noted down. An extensive ophthalmological examination was performed, that included evaluation of the orbit, eyelid, front and back parts of the eyes. Comprehensive health evaluations involve assessing thyroid function, conducting a complete blood count (CBC) and analyzing other pertinent blood indicators. These tests were conducted to identify any anatomical abnormalities including routine imaging investigations

such as X-rays of orbit, skull and sinuses. Advanced imaging techniques such as magnetic resonance imaging (MRI), dye-contrast orbitography, internal carotid arteriography, orbital tomography and specialized views of optic foramina were used to get to determine the causes of proptosis. Thyroid function tests (TFTs), including measurements of thyroid-stimulating hormone (TSH) as well as levels of thyroid hormones (free T3 and free T4), were employed to assess for the presence of thyrotoxicosis. The histopathological investigation was used to confirm the diagnosis of suspicious neoplasms. The collected data were examined to determine the frequency of thyrotoxicosis and other factors that contribute to unilateral proptosis. The statistical analyses were conducted using SPSS version 26.0 software, applying descriptive statistics to summarize patient demographics, clinical results and diagnostic outcomes. The associations between the presence of thyrotoxicosis and demographic variables were assessed using chi-square tests.

The sample size for this study was determined based on the expected prevalence of unilateral proptosis caused by thyrotoxicosis or other factors, along with a margin of error and confidence level. Given an expected prevalence of 10%, a confidence level of 95%, and available resources, the researchers aimed to achieve a balance between precision and feasibility. The sample size was calculated using the formula.

$$d^2 = z^2 \cdot p \cdot (1-p) / n$$

Where;

z is the z -value for a 95% confidence level (1.96), p is the expected prevalence (10%) and n is the sample size. This margin of error (7.5%) was considered acceptable given the practical constraints and the study's aims, leading to a final sample size of 62 participants.

RESULTS

An in-depth analysis of the demographic characteristics of patients with unilateral proptosis revealed their mean age as 27.84 ± 6.8 years, with a range of 15-60 years. A younger age prevalence was shown by the fact that 67.7% of patients fell between the ages of 15 and 30. The female population constitutes 54.8% of the total, while the male population made 45.2%. Additional symptoms included double vision (33.9%), discomfort (14.5%), elevated body temperature (11.3%) and decreased visual acuity (4.8%) ($p > 0.05$) (Table 1).

Table 1: Detailed Demographics of Patients with Unilateral Proptosis

Parameter	n (%)
Age (Years)	
Mean \pm SD	27.84 \pm 6.8
Range	15-60 Years

Age Groups	
15-30	42 (67.7)
31-45	12 (19.4)
46-60	8 (12.9)
Gender	
Male	28 (45.2)
Female	34 (54.8)
Associated Symptoms	
Diplopia	21 (33.9)
Pain	9 (14.5)
Fever	7 (11.3)
Vision Loss	3 (4.8)

The incidence of thyrotoxicosis was higher in female (73.5%) compared to male (53.6%). But there was no statistically significant relationship between sex and incidence of thyrotoxicosis ($p > 0.05$) (Figure 1).

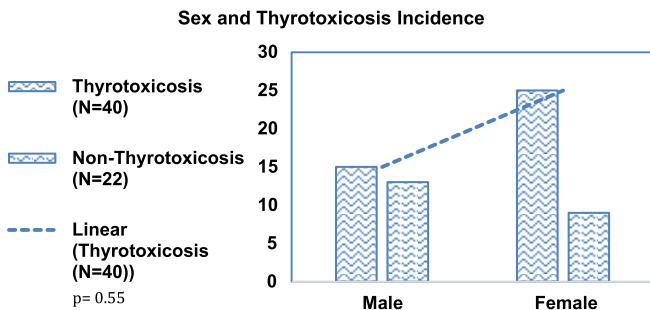


Figure 1: Association between Sex and Thyrotoxicosis Incidence

The distribution of etiologies by age group showed that thyrotoxicosis was most commonly found in 15-30 age range, with a prevalence rate of 62.5%. Retrobulbar tumors exhibit a reasonably uniform distribution across different age groups, but cavernous sinus thrombosis was most commonly observed in individuals aged 31-45, accounting for 50% of cases. Idiopathic proptosis was seen in individuals of all age groups, however it was slightly more prevalent in younger individuals ($p < 0.05$) (Table 2).

Table 2: Distribution of Etiologies by Age Group

Age Group (Years)	Thyrotoxicosis (n=40)	Retrobulbar Tumor (n=10)	Cavernous Sinus Thrombosis (n=8)	Idiopathic Proptosis (n=4)	Chi-Square	p-Value
15-30	25 (62.5)	4 (40.0)	2 (25.0)	2 (50.0)	5.67	0.046*
31-45	11 (27.5)	3 (30.0)	4 (50.0)	1 (25.0)		
46-60	4 (10.0)	3 (30.0)	2 (25.0)	1 (25.0)		

The correlation between sex and several causes of proptosis was also examined. Thyrotoxicosis had higher prevalence in female (73.5%) compared to the male (53.6%). The frequency of retrobulbar tumors, cavernous sinus thrombosis, and idiopathic proptosis were similar in both male and female, indicating non-significant relationship between sex and various proptosis etiologies (Table 3).

Table 3: Association between Gender and Different Proptosis Etiologies

Etiologies	Male (n=28)	Female (n=34)	Total (n=62)	Chi-Square	p-Value
Thyrotoxicosis	15 (53.6)	25 (73.5)	40 (64.5)	2.87	0.41
Retrobulbar Tumor	5 (17.9)	5 (14.7)	10 (16.1)		
Cavernous Sinus Thrombosis	5 (17.9)	3 (8.8)	8 (12.9)		
Idiopathic Proptosis	3 (10.7)	1 (2.9)	4 (6.5)		

The prevalence of thyrotoxicosis was higher in the younger age group (15-30 years), with an incidence rate of 62.5%. The occurrence was less frequent in older age groups, indicating a decrease in frequency as age increases ($p < 0.05$), suggesting that age did not play a large role in determining the occurrence of thyrotoxicosis (Table 4).

Table 4: Incidence of Thyrotoxicosis in Various Age Groups

Age Group (Years)	Male (n=15)	Female (n=25)	Total (n=40)	Chi-Square	p-Value
15-30	10 (66.7)	15 (60.0)	25 (62.5)	3.22	0.05*
31-45	3 (20.0)	8 (32.0)	11 (27.5)		
46-60	2 (13.3)	2 (8.0)	4 (10.0)		

Thyrotoxicosis was linked to the greatest percentage of diplopia (45.0%), discomfort (17.5%) and fever (10.0%). Other causes exhibited lesser frequency of symptoms, whereas idiopathic proptosis did not present any accompanying symptoms. It also suggested that there was no statistically significant difference in the distribution of symptoms among distinct causes ($p < 0.05$) (Table 5).

Table 5: Associated Symptoms by Etiology

Etiologies	Diplopia	Pain	Fever	Vision Loss	Chi-Square	p-Value
Thyrotoxicosis (n=40)	18 (45.0)	7 (17.5)	4 (10.0)	2 (5.0)	4.12	0.028*
Retrobulbar Tumor (n=10)	2 (20.0)	1 (10.0)	1 (10.0)	0 (0.0)		
Cavernous Sinus Thrombosis (n=8)	1 (12.5)	1 (12.5)	1 (12.5)	1 (12.5)		
Idiopathic Proptosis (n=4)	0 (0.0)	0 (0.0)	0 (0.0)	0 (0.0)		

DISCUSSION

The main objective of the study was to assess the frequency of thyrotoxicosis in patients who had unilateral proptosis. Our findings indicated that the disorder primarily affected female and people in younger age brackets. The study findings indicated that thyrotoxicosis was the predominant underlying cause [16]. The high occurrence of this condition emphasized the importance of considering thyrotoxicosis as a significant potential cause of unilateral proptosis. The predominance of female affected by thyroid eye illness, as observed in our study, corresponded with worldwide patterns. Multiple studies [16-19] consistently indicated a higher prevalence of the disease in female compared to male. Within our dataset, the proportion of female patients was 54.8%, which supported this observation. The statistics also showed a mean patient age

of 27.84 years, which aligned with the results of prior studies. For example, Zarei *et al.*, [19] found that the average age was 34 ± 12.0 years, but Khan *et al.*, [20] observed a significantly higher average age of 44.8 ± 12.4 years. In our investigation, retrobulbar tumors were found responsible for 16.1% of cases with unilateral proptosis, in addition to the high occurrence of thyrotoxicosis. Cavernous sinus thrombosis, characterized by the formation of blood clots in the cavernous sinus located at the base of the brain, was observed in 10.6% of cases. This issue can lead to serious eye difficulties and needs to be quickly identified and treated. A tiny percentage of instances exhibited idiopathic proptosis, however, it is important to evaluate the presence of small masses, cysts, and reactive hyperplasia in cases where the cause of proptosis is not immediately apparent. Therefore, it is recommended to perform MRI imaging of the brain and orbit in all cases with unilateral proptosis to thoroughly investigate potential reasons. The incidence rate of thyrotoxicosis was considerably higher in the younger age group (15–30 years). This implied that thyrotoxicosis is more likely to develop in younger individuals as a cause of unilateral proptosis than in older age groups. The lower incidence in older age groups suggested that age is a significant factor in the development of thyrotoxicosis [20–24]. Among the etiologies examined, thyrotoxicosis was associated with the highest percentage of diplopia, distress, and fever. These symptoms were significantly associated with thyrotoxicosis, emphasizing the significance of taking these clinical presentations into account when diagnosing thyrotoxicosis in patients with proptosis. The necessity of comprehensive clinical evaluations, which include detailed symptom assessments, to guarantee accurate diagnosis and expeditious treatment is underscored by the substantial correlation between these symptoms and thyrotoxicosis [25]. Exophthalmos (protrusion of eyeballs) is a frequently observed sign of this eye disease. It is most common during the initial year of the disease's onset. During the second year, occurrence of thyrotoxic goiter became more common, affecting around 60 to 80% of cases [26]. Nevertheless, the extent of exophthalmos may not exhibit a direct correlation with the intensity of thyrotoxicosis, since substantial protrusion can occur even in the presence of relatively minor thyroid symptoms [27]. Macovei observed that a small proportion of individuals with exophthalmic goiter exhibited a reduced basal metabolic rate, typically falling within the range of plus 10 to plus 20% [28]. Exophthalmos may occur before other clinical indications of thyrotoxicosis in exceptionally uncommon instances. There are only a few studies in the literature that describe this phenomenon, with eight reported occurrences where exophthalmos appeared prior to any indications of

thyrotoxicosis. Nevertheless, even in these instances, the reliability of certain accounts seems uncertain [29]. Thyrotropic exophthalmos, which is caused by excessive release of thyrotropic hormone from the pituitary gland, can develop when there is an excess of male hormones and insufficient levels of thyroxine. The significance of doing a comprehensive endocrine evaluation in the diagnosis and treatment of unilateral proptosis is emphasized by this condition [30]. The significant findings of this study provided valuable insights into the characteristics and potential predictors of thyrotoxicosis. Furthermore, the etiology of unilateral proptosis could be further clarified by investigating supplementary factors, including genetic predispositions and environmental influences.

CONCLUSIONS

Thyrotoxicosis was identified as the primary cause of unilateral proptosis, particularly affecting young women. We recommend comprehensive evaluation for thyrotoxicosis in all proptosis cases, including thyroid function tests and MRI to rule out other etiologies. The significant association with symptoms such as diplopia, discomfort, and fever underscores the need for thorough clinical assessment to ensure accurate diagnosis and prompt treatment.

Authors Contribution

Conceptualization: SK, NUR

Methodology: SK, AR

Formal analysis: AR, RN

Writing-review and editing: SK, NUR, AR

All authors have read and agreed to the published version of the manuscript.

Conflicts of Interest

The authors declare no conflict of interest.

Source of Funding

The authors received no financial support for the research, authorship and/or publication of this article.

REFERENCES

- [1] Zafar T, Perveen S, Khan N, Ahmed T. Frequency of Thyrotoxicosis in Patient with One Sided Exophthalmos. *RADS Journal of Pharmacy and Pharmaceutical Sciences*. 2020 Nov; 8(2): 81-4. doi: 10.37962/jpps.v8i2.373.
- [2] Ackuaku-Dogbe EM, Akpalu J, Abaidoo B. Epidemiology and clinical features of thyroid-associated orbitopathy in Accra. *Middle East African Journal of Ophthalmology*. 2017 Oct; 24(4): 183-9. doi: 10.4103/meajo.MEAJO_91_17.
- [3] Delyfer MN, Gaucher D, Govare M, Coughnard-Grégoire A, Korobelnik JF, Ajana S *et al.* Adapted surgical

- procedure for Argus II retinal implantation: feasibility, safety, efficiency, and postoperative anatomic findings. *Ophthalmology Retina*. 2018 Apr; 2(4): 276-87. doi: 10.1016/j.oret.2017.08.010.
- [4] Gharib S, Moazezi Z, Bayani MA. Prevalence and severity of ocular involvement in Graves' disease according to sex and age: A clinical study from Babol, Iran. *Caspian Journal of Internal Medicine*. 2018; 9(2): 178.
- [5] Tanda ML, Piantanida E, Liparulo L, Veronesi G, Lai A, Sassi L et al. Prevalence and natural history of Graves' orbitopathy in a large series of patients with newly diagnosed graves' hyperthyroidism seen at a single center. *The Journal of Clinical Endocrinology & Metabolism*. 2013 Apr; 98(4): 1443-9. doi: 10.1210/jc.2012-3873.
- [6] Teja N, Reddy M, Vanama A. An etiological analysis of proptosis. *International Journal of Research in Medical Sciences*. 2017 Jan; 3(10): 2584-8. doi: 10.18203/2320-6012.ijrms20150795.
- [7] Zahir SI, Khan MU, Ahmad M, Hussain I, Hamayun J. Etiological Pattern, Clinical Presentation and Outcome of Patients with Proptosis in a Tertiary Care Hospital. *Pakistan Armed Forces Medical Journal*. 2022; 72(6): 2113-16. doi: 10.51253/pafmj.v72i6.6097.
- [8] Agha A, Pangy T, Ajayi O, Solomon AL. Septic cavernous sinus thrombosis; a rare cause of unilateral exophthalmos. *The Ulster Medical Journal*. 2020 Sep; 89(2): 131.
- [9] Paul S, Tost F, Hübner BC. Unilateral Exophthalmos. *Deutsches Ärzteblatt International*. 2022 Sep; 119(37): 618. doi: 10.3238/arztebl.m2022.0128.
- [10] Si AS, Benoumechiara I, Fedala NS. When unilateral exophthalmos is the only manifestation of graves. *In Endocrine Abstracts* 2022 May; 81. doi: 10.1530/endoabs.81.EP1135.
- [11] Keenswijk W, Degraeuwe E, Hoorens A, Dorpe JV, Vande Walle J. A case of Graves' disease associated with membranoproliferative glomerulonephritis and leukocytoclastic vasculitis. *Journal of Pediatric Endocrinology and Metabolism*. 2018 Oct; 31(10): 1165-8. doi: 10.1515/jpem-2018-0186.
- [12] Fuchs AA, Walker KE, Adkins PR, Donnelly KS, Giuliano EA. Diagnosis and surgical management of a retrobulbar abscess causing unilateral exophthalmos in a Boer goat. *Veterinary Ophthalmology*. 2021 Nov; 24(6): 639-44. doi: 10.1111/vop.12906.
- [13] Muammar AR and Khan AA. SAT-490 A Case of Unilateral Exophthalmos Due to Thyroid Orbitopathy and Its Association with Chronic Kidney Disease. *Journal of the Endocrine Society*. 2020 Apr; 4(1): 490. doi: 10.1210/jendso/bvaa046.1403.
- [14] Bouktib Y, Abidine E, Boutakioute B, El Hajjami A, Amenzouy F, Idrissi MO et al. Intraorbital Cavernous Hemangioma: Rare Cause of Exophthalmos. *Scholars Journal of Medical Case Reports*. 2023 Apr; 4: 707-10. doi: 10.36347/sjmcr.2023.v11i04.072.
- [15] Takeda Y, Suzuki H, Hosono K, Hikoya A, Komori M, Inagaki R et al. Exophthalmos associated with chronic progressive external ophthalmoplegia. *Japanese Journal of Ophthalmology*. 2022 May; 66(3): 314-9. doi: 10.1007/s10384-022-00920-5.
- [16] Tauber J, Polla DJ, Park S. Exophthalmos in Kearns-Sayre syndrome. *Journal of American Association for Pediatric Ophthalmology and Strabismus*. 2019 Oct; 23(5): 295-7. doi: 10.1016/j.jaapos.2019.05.005.
- [17] Chehade LK, Rajak SN, Selva D. Proptosis secondary to third nerve palsy. *Clinical & Experimental Ophthalmology*. 2017 Dec; 45(9). doi: 10.1111/ceo.12987.
- [18] Bhattarai HB, Thapaliya I, Dhungana S, Singh PB, Bhattarai M, Pokhrel B et al. Unilateral proptosis in a patient with thyroid eye disease: A case report. *SAGE Open Medical Case Reports*. 2023 Jul; 11: 2050313X231190669. doi: 10.1177/2050313X231190669.
- [19] Zarei S, Vo P, Sam C, Crow RW, Stout C, Al-Khoury L. Acute bilateral blindness in the setting of sudden onset of bilateral proptosis and ophthalmoplegia: a case report with literature review. *Neurology: Clinical Practice*. 2021 Oct; 11(5): e706-13. doi: 10.1212/CPJ.00000000001090.
- [20] Khan AA, Mahmoud Muammar AR, Kamal I. A case of unilateral exophthalmos due to thyroid orbitopathy in a clinically euthyroid patient. *World Journal of Advanced Research and Reviews*. 2019; 9: 1-3. doi: 10.31871/WJRR.9.6.6.
- [21] Bojikian KD and Francis CE. Thyroid eye disease and myasthenia gravis. *International Ophthalmology Clinics*. 2019 Jul; 59(3): 113-24. doi: 10.1097/IIO.000000000000277.
- [22] Yang J, Hu X, Li Q, Huang RL. Botulinum Toxin Type A Injection for Correction of Upper Eyelid Retraction in Thyroid-Associated Ophthalmopathy. *Journal of Craniofacial Surgery*. 2023 Jul; 34(5): e485-8. doi: 10.1097/SCS.00000000000009347.
- [23] Segni M. Disorders of the Thyroid Gland in Infancy, Childhood and Adolescence. [Updated 2017 Mar 18]. South Dartmouth(MA): Endotext[Internet]; 2000.
- [24] Blick C, Nguyen M, Jialal I. Thyrotoxicosis. [Updated 2023 Jul 4]. In: StatPearls [Internet]. Treasure Island (FL): StatPearls Publishing; 2024.
- [25] Men CJ, Kossler AL, Wester ST. Updates on the understanding and management of thyroid eye disease. *Therapeutic advances in ophthalmology*.

- 2021 Jun; 13: 25158414211027760. doi: 10.1177/25158414211027760.
- [26] Stephen MA, Ahuja S, Jayasri P, Harigaravelu PJ. Peripheral primitive neuroectodermal tumor of the orbit in Graves' ophthalmopathy-A rare presentation. *Saudi Journal of Ophthalmology*. 2023 Jan; 37(1): 69-71. doi: 10.4103/sjopt.sjopt_143_21.
- [27] Macovei ML and Azis Ū. A case report of a patient with severe thyroid eye disease. *Romanian Journal of Ophthalmology*. 2022 Apr; 66(2): 153. doi: 10.22336/rjo.2022.30.
- [28] Ahmed I and Al Ibrahim S. Abstract# 1318463: Severe Unilateral Exophthalmos as Early Presentation of Hashimoto's Thyroiditis. *Endocrine Practice*. 2022 Dec; 28(12): S64. doi: 10.1016/j.eprac.2022.10.135.
- [29] Weng CY. Retrobulbar Hematoma in a Patient with Thyroid Eye Disease. *Journal of Emergencies, Trauma, and Shock*. 2022 Oct; 15(4): 188-9. doi: 10.4103/jets.jets_164_21.
- [30] Shahid MA, Ashraf MA, Sharma S. Physiology, Thyroid Hormone. [Updated 2023 Jun 5]. In: StatPearls [Internet]. Treasure Island (FL): StatPearls Publishing; 2024 Jan-. Available from: <https://www.ncbi.nlm.nih.gov/books/NBK500006/>