



## Original Article

## Clinical Study of the Manifestations of Diabetes Mellitus in Oral Cavity

Basil Khalid<sup>1</sup>, Muhammad Athar Khan<sup>2</sup>, Marij Hameed<sup>3</sup>, Samar Nazir<sup>3\*</sup>, Ehsan Haider<sup>1</sup> and Ammara Nazir<sup>2</sup><sup>1</sup>Multan Medical and Dental College, Multan, Pakistan<sup>2</sup>Bakhtawar Amin Medical and Dental College, Multan, Pakistan<sup>3</sup>Combined Military Hospital Dental College, Multan, Pakistan

## ARTICLE INFO

**Keywords:**

Diabetes, Medically Compromised Patients, Oral Mucosal Lesions, Periodontitis

**How to Cite:**Khalid, B., Khan, M. A., Hameed, M., Nazir, S., Haider, E., & Nazir, A. (2024). Clinical Study of the Manifestations of Diabetes Mellitus in Oral Cavity: Clinical Study of the Manifestations of Diabetes Mellitus. *Pakistan Journal of Health Sciences*, 5(07). <https://doi.org/10.54393/pjhs.v5i07.1672>**\*Corresponding Author:**Samar Nazir  
Combined Military Hospital Dental College, Multan,  
Pakistan  
[omfsurgery\\_pakistan@hotmail.com](mailto:omfsurgery_pakistan@hotmail.com)Received Date: 9<sup>th</sup> May, 2024Acceptance Date: 25<sup>th</sup> July, 2024Published Date: 31<sup>st</sup> July, 2024

## ABSTRACT

Diabetes Mellitus, a chronic illness affecting all ages, contributes to worldwide mortality and morbidity. Oral consequences of diabetes are less well-documented than microvascular and macrovascular issues. It's been called a growing endemic disease. About 285 million people worldwide have diabetes. **Objectives:** To enhance the understandings of oral signs and the complications associated particularly with Diabetes Mellitus. **Methods:** Patients aged 40 to 75 were included in the study without gender discrimination All patients were known diabetic (NIDDM) and having the disease from at least last 7 years. clinical values and labs (RBS and HbA1C were taken to assess the control level of the disease) were taken from their record files. **Results:** Family history of non-idiopathic diabetic retinopathy (NIDDM) was found in (59.44%) of the population. NIDDM caused oral lesions in close to (79.34%) of individuals. 13 patients presented with white lesions. Buccal mucosa remained the most common site of involvement, with desquamative gingival involvement in 3 patients. Oral Lichen Planus was seen in 13 patients (2.53%). Halitosis in 309 patients (60.23%), Mild xerostomia in 184 patients (35.87%), tooth mobility >2mm was found in 106 patients (20.66%), Angular Cheilitis seen in 51 patients (9.94%), and oral ulcers / RAS were reported in 117 patients (22.81%). **Conclusions:** NIDDM can cause oral mucosal pathologies. Routine dental screenings and early detection of these alterations may improve oral health, medication adherence, and problems in afflicted persons.

## INTRODUCTION

The endocrine condition known as diabetes is characterized by an abnormal metabolism of carbohydrates, protein, glucose, and fat or lipids. Diabetes is a condition that does not ever go away [1]. The inability to either produce or respond to insulin is the hallmark of this disease, which is characterized by persistently high levels of glucose in the bloodstream. These levels, if allowed to remain elevated for an extended period of time, have the potential to cause damage to a number of vital organs in the body, including the kidneys, blood vessels, nerves, and heart. Idiopathic diabetic retinopathy (IDDM) and non-idiopathic diabetic retinopathy (NIDDM) are the two primary types of diabetes [2, 3]. IDDM, also known as Type 1, is a form of diabetes that first manifests itself in infants or young children and accounts for approximately 10 to 15

percent of all patients who are diagnosed with diabetes mellitus. This is because to the elimination of beta islets of Langerhan cells in the pancreas, which is caused by an autoimmune response. Diabetes mellitus type 1 (NIDDM), also known as adult-onset diabetes, is a form of diabetes that is more prevalent and recurrent [4]. A wide variety of oral manifestations have been observed in patients who are medically compromised, according to the findings of a number of researchers. Individuals who have diabetes that is not under control are at a greater risk of developing certain infections, such as fungal and viral infections, which are essential to the consequences of hyperglycemia that has been present for a long time. To achieve the goal of achieving a world free of diabetes and obesity by the year 2025, everyone is fully committed to meeting this objective

[5, 6]. Problems can arise in many different parts of the body, including the mouth, when blood sugar levels remain consistently high for an extended period of time. As a consequence of this, it is possible to effectively avoid these consequences by maintaining proper control of the levels of glucose in the blood. There are a number of potential mechanisms that are associated with diabetic oral complications. Some of these mechanisms include hypoxia, microangiopathy, neuropathy, microvascular changes, increased glucose levels in saliva, dehydration, and impaired neutrophil function (chemotaxis steps)[7]. It is possible for this kind of infection to take place when the pH is low and the saliva is low. SIAG, C-reactive protein, serum amyloid A, interleukin-6, cortisol, and sialic acid alpha-1 acid glycoprotein are inflammatory indicators related with NIDDM. For this reason, the sick note should include oral symptoms [8]. Xerostomia, tooth and root caries, periodontal lesions, gingivitis, gum disease, oral candidiasis, B.M.S., altered taste feelings, oral lichen planus, recurrent aphthous a condition called raised infection risk, and poor wound healing following minor oral surgical procedures are all oral manifestations and complications that can respond to D.M. High blood sugar levels, both in terms of length and intensity, are often connected with the severity of diabetic complications [9, 10]. The diagnosis of Diabetes Mellitus is established by examining blood glucose levels. For F.B.S. levels > 126mg/dl or R.B.S. levels > 200mg/dl, the diagnosis of D.M. is established, cemented by a HbA1C level > 6.4%. A normal HbA1C level is below 5.7%. 5.7% to 6.4% suggests prediabetes, whereas levels greater than 6.5% indicate diabetes. The bigger the HbA1C with pre-diabetic readings, the greater is the chance of developing NIDDM[11].

This study aimed to increase our understanding of oral symptoms and the repercussions that are frequently linked with diabetes mellitus that does not depend on insulin.

## METHODS

This descriptive study was comprised of 513 patients. The data were collected over a time period of 11 months Feb 2023-Dec 2023. Ethical review board of CIMS Dental College Multan approved research on with(Ref no 786/CDC-20MDC/IRB 2-07). All patients were known diabetic (NIDDM) and having the disease from at least last 7 years. Patients aged 40 to 75 were included in the study without gender discrimination. Also patients who regularly used oral stimulants such as pan, betel nut, snuff, tobacco, or alcohol were excluded. Their clinical values and labs (RBS and HbA1C were taken to assess the control level of the disease) were taken from their record files. Patient details encompassing demographic data, oral hygiene practices, and past medical and dental history were documented. Examination was conducted using a mouth mirror and CPITN probe. All oral anatomical sites(soft and hard tissues

including lips, gingiva, tongue, alveolar bone, dental tissues and palate) were examined, and relevant information was recorded. Consent of the patients was obtained and appointment for biopsy was given. After successfully managing diabetes mellitus, the patient's physician gave their authorization for the biopsy to be taken. In order to administer the local anesthetic solution, the patient was positioned in a dental chair and instructed to sit still. Injecting 0.2% lidocaine around the biopsy site allowed for precise histological analysis. The buccal mucosa was then carefully removed using tissue forceps after a tiny section had been sliced with a Bard-Parker blade. The tissue was fixed in a 10% formalin solution after the biopsy site was sutured. The standard protocols were used to prepare 5µm paraffin slices from the tissue. The sections were stained using the H and E procedure, which stands for hematoxylin and eosin. Statistical test was applied to check oral manifestation in gender, which was determined by analyzing the data using SPSS software version 27.0 for comprehensive elaboration and comparison. In order to show the data, the mean and standard deviation were utilized.

## RESULTS

Out of 513 patients in studies, 193 were male (37.62%), and females 320 were (62.38%). The male-to-female ratio was 1:1.66 The Mean age of patients was 54.16 years with an age range of 50-80 years. The study revealed that 383 patients (74.66%) had poor oral hygiene, 96 patients (18.71%) had moderate oral hygiene, and only 34 patients (6.63%) had good oral hygiene. Family history of NIDDM was found in 59.4% of the population. NIDDM caused oral lesions in close to 79.34% of individuals (Table 1).

**Table 1:** Demographics of the Enrolled Cases

Variables	Frequency (%)
Male	193
Female	320
Total	513
Mean Age (Years)	54.16
<b>Oral Hygiened</b>	
Poor	383 (74.66%)
Moderate	96 (18.71%)
Good	34 (6.63%)
<b>Family History of NIDDM</b>	
Yes	305 (59.4%)
No	208 (40.6%)
<b>Oral Lesions</b>	
Yes	407 (79.34%)
No	106 (20.66%)

It was found that, mean HbA1c was 7.6%, mean RBS was 201.15 mg/dl and mean RBS was 177.13mg/dl. These findings indicated that presence of DM in patients (Table 2).

**Table 2:** Blood Glucose Levels among Presented Cases

Variables	Mean Value
HbA1c %	7.6%
RBS mg/dl	201.15
RBS mg/dl	177.13

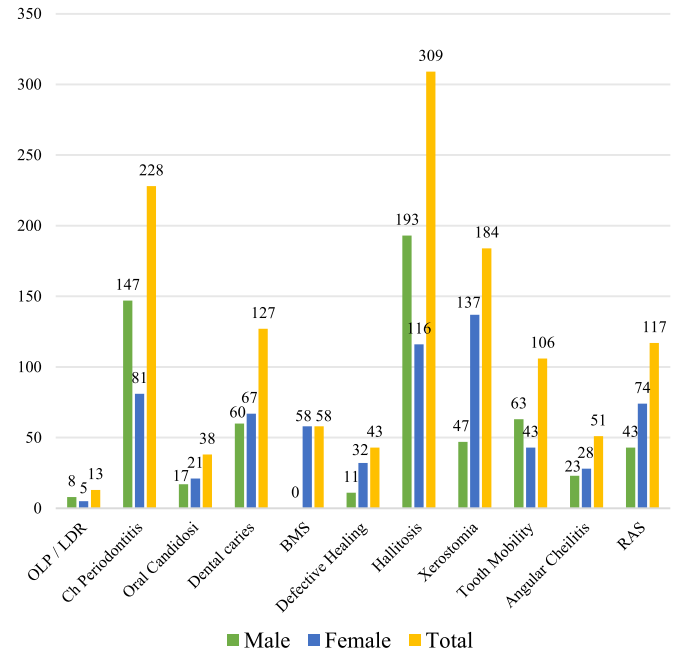
Different oral mucosal lesions were present as an effect of NIDDM in 407 patients (79.33 %). 13 patients presented with white lesions. Buccal mucosa remained the most common site of involvement, with desquamative gingival involvement in 3 patients. These lesions were regarded as Oral lichen planus (OLP) or Lichenoid drug reactions (LDR) based on their clinical presentations and the long-term history of drug intake (oral hypoglycemics). The oral pathologist studied the microscopic examination of 6 cases to confirm them as an erosive type of OLP., and three as a reticular type. Four patients refused h/p (Table 3).

**Table 3:** Oral Manifestations of NIDDM

Oral Manifestations	Male	Female	Total
	N 193 (%)	N 320 (%)	N 513 (%)
Oral Mucosal lesions	39 (7.61)	67 (13.1)	407 (79.33)
OLP	8 (1.55)	5 (1)	13 (2.53)
Chronic Periodontitis	147 (28.65)	81 (1.58)	228 (44.44)
Oral Candidosis	17 (3.31)	21 (4.1)	38 (7.41)
Dental Caries	60 (11.69)	67 (13.1)	127 (24.76)
BMS	0 (0)	58 (11.31)	58 (11.31)
Delayed / Defective Healing	11 (2.14)	32 (6.24)	43 (8.39)
Halitosis	193 (37.62)	116 (22.61)	309 (60.23)
Mild Xerostomia	47 (9.16)	137 (26.7)	184 (35.87)
Tooth Mobility	63 (12.28)	43 (8.38)	106 (20.66)
Angular Cheilitis	23 (4.48)	28 (5.46)	51 (9.94)
RAS	43 (8.38)	74 (14.42)	117 (22.81)

Chronic periodontitis (pocket depths >4mm with bleeding gums and Halitosis) was found in 228 patients (44.44%), oral candidiasis was seen in 38 patients (7.41%), significant dental caries was reported in 127 patients (24.76%), burning sensations /BMS was present in 58 patients (11.31%), defective or delayed wound healing after minor oral surgical procedures was found in 43 patients (8.39%), Oral Lichen Planus was seen in 13 patients (2.53%). Halitosis in 309 patients (60.23%), Mild xerostomia in 184 patients (35.87%), tooth mobility >2mm was found in 106 patients (20.66%), Angular Cheilitis seen in 51 patients (9.94%), and oral ulcers / RAS were reported in 117 patients (22.81%). One patient had multiple findings in these results (Figure 1).

**Oral manifestations of NIDDM**



**Figure 1:** Oral Manifestation of NIDDM with respect to Gender

## DISCUSSION

There are over 537 million diabetic patients worldwide, almost 1 in every 10 individuals. Even this number is expected to rise up to over 643 million in 2030. Being a developing country with limited resources, Pakistan ranks at number 3 in global diabetes prevalence. Over 19 million people are living with diabetes in Pakistan. Diabetes Mellitus comprises a range of metabolic disorders that impact nearly every part of the body, including a wide range of presentations in the oral cavity, affecting oral mucosal linings. In the current study, the Mean age of patients is 54.16 years, with the age group of 40-75 years. Bastos [10] and co-workers from Brazil reported the mean age of NIDDM patients as 50.3 years. In another study from Pakistan, the mean age of D.M. is 53.1 years, aged 40-70 [11]. The global disparities in such data occur due to geographical differences, other environmental factors like diet and lifestyle, and the health awareness facilities available. In addition, this difference may also be because we have included a wide range of mucosal lesions in the oral cavity in the study and not any single entity [12]. Advanced glycation end products are formed in hyperglycemia, which is characterized by chronically elevated blood sugar levels. Substances (A.G.E.s) in the tissues and other metabolic disorders [13]. The mouth and teeth are vulnerable to the unanticipated consequences of these A.E.G.s. Delays in wound healing occur when fibroblasts, which are responsible for periodontium repair, connect with A.G.E.s in an environment with high glucose levels, rendering them unable to repair the damaged collagen [14, 15]. As a result, periodontal support is compromised and teeth become

more mobile, and bone resorption and collagen fiber breakdown occur. Periodontal tissues are more susceptible to infections when blood sugar levels are high (hyperglycemia), which causes oxidative stress to build up. The inflammation in periodontal tissues, which is characteristic of periodontitis, is worsened by diabetes since the disease is intrinsically pro-inflammatory. This is demonstrated by elevated levels of reactive oxygen species (ROS) and inflammatory cytokines [16-20]. Because of both the disease itself and the medications used as oral hypoglycemics, there is a strong correlation between oral lichen planus and lichenoid drug reactions in patients with diabetes mellitus [21-23]. Nevertheless, additional research is need to confirm the connection and associations. The sixth main consequence of poorly controlled diabetes in both NIDDM and IDDM patients is aggressive periodontitis, which is now widely acknowledged.

## CONCLUSIONS

Dental issues and oral mucosal problems are significant yet often overlooked complications of diabetes, which escalate with the duration and management of the condition. Regular dental check-ups for routine screening and prompt identification of these changes can enhance oral health, promote adherence to drug therapy, and mitigate complications in affected individuals. Additional research, in collaboration with physicians and endocrinologists, and thorough examinations are necessary to ascertain the precise types and frequency of dental issues related to diabetes. Moreover, evaluating the management of diabetes alongside periodontal disease treatment is essential.

## Authors Contribution

Conceptualization: MTK, BK

Methodology: BK

Formal analysis: MH, SN

Writing, review and editing: EH, AN

All authors have read and agreed to the published version of the manuscript.

## Conflicts of Interest

The authors declare no conflict of interest.

## Source of Funding

The authors received no financial support for the research, authorship and/or publication of this article.

## REFERENCES

- [1] Fernandes JDL, Bomfim RM, França CR, Carneiro GKM, Silva ACR da, Nascimento Neto EV do et al. Oral manifestations in Patients with Diabetes mellitus. *Research, Society and Development*. 2022 Sep; 11(12): 1-7. doi: 10.33448/rsd-v11i12.34330.
- [2] Alhazmi YA, Parveen S, Alfaifi WH, Najmi NM, Namazi SA, Abuzawah LH et al. Assessment of Knowledge, Attitude and Practice of Diabetic Patients towards Oral Health: A Cross-Sectional Study. *World Journal of Dentistry*. 2022 Apr; 13: 239-44. doi: 10.5005/jp-journals-10015-1922.
- [3] Malekmahmoodi M, Shamsi M, Roozbahani N, Moradzadeh R. A Randomized Controlled Trial of an Educational Intervention to Promote Oral and Dental Health of Patients with Type 2 Diabetes Mellitus. *BMC Public Health*. 2020 Dec; 20: 1-9. doi: 10.1186/s12889-020-8395-4.
- [4] Hsu PC, Wu HK, Huang YC, Chang HH, Lee TC, Chen YP et al. The Tongue Features Associated with Type 2 Diabetes Mellitus. *Medicine*. 2019 May; 98(19): 1-6. doi: 10.1097/MD.00000000000015567.
- [5] Ahmad P, Akhtar U, Chaudhry A, Rahid U, Saif S, Asif JA. Repercussions of Diabetes Mellitus on the Oral Cavity. *European Journal of General Dentistry*. 2019 Sep; 8(03): 55-62. doi: 10.4103/ejgd.ejgd\_28\_19.
- [6] Ahmad R and Haque M. Oral Health Messiers: Diabetes Mellitus Relevance. *Diabetes, Metabolic Syndrome and Obesity*. 2021 Jul; 3001-15. doi: 10.2147/DMSO.S318972.
- [7] Manish K, Raman N, Gautam A, Jain S, Jha PC, Kumar A. A Study on Association of Tooth Loss and Periodontal Disease in Patients Suffering from Diabetes from Bihar Region. *International Journal of Medical and Biomedical Studies*. 2020 Feb; 4(2): 220-6. doi: 10.32553/ijmbs.v4i2.977
- [8] Ateeq H, Zia A, Husain Q, Khan MS, Ahmad M. Effect of Inflammation on Bones in Diabetic Patients with Periodontitis via RANKL/OPG system- A Review. *Journal of Diabetes & Metabolic Disorders*. 2022 Jun; 21(1): 1003-9. doi: 10.1007/s40200-021-00960-7.
- [9] Bastos AS, Graves DT, Loureiro AP, Rossa Júnior C, Abdalla DS, Faulin TD et al. Lipid Peroxidation is Associated with the Severity of Periodontal Disease and Local Inflammatory Markers in Patients with Type 2 Diabetes. *The Journal of Clinical Endocrinology & Metabolism*. 2012 Aug; 97(8): 1353-62. doi: 10.1210/jc.2011-3397.
- [10] Battancs E, Gheorghita D, Nyiraty S, Lengyel C, Eördegh G, Baráth Z et al. Periodontal disease in diabetes mellitus: A Case-Control Study in Smokers and Non-smokers. *Diabetes Therapy*. 2020 Nov; 11: 2715-28. doi: 10.1007/s13300-020-00933-8.
- [11] Sundar C, Ramalingam S, Mohan V, Pradeepa R, Ramakrishnan MJ. Periodontal Therapy as an Adjunctive Modality for HbA1c Reduction in Type-2 Diabetic Patients. *Journal of Education and Health Promotion*. 2018 Jan; 7(1): 1-7. doi: 10.4103/jehp.jehp\_

- 66\_18.
- [12] Polak D, Sanui T, Nishimura F, Shapira L. Diabetes as a Risk Factor for Periodontal Disease—Plausible Mechanisms. *Periodontology* 2000. 2020 Jun; 83(1): 46-58. doi: 10.1111/prd.12298.
- [13] Mayta-Tovalino F, Mendoza-Martiarena Y, Romero-Tapia P, Álvarez-Paucar M, Gálvez-Calla L, Calderón-Sánchez J et al. An 11-Year Retrospective Research Study of the Predictive Factors of Peri-Implantitis and Implant Failure: Analytic-Multicentric Study of 1279 Implants in Peru. *International Journal of Dentistry*. 2019 Jun; 2019(1): 2-8. doi: 10.1155/2019/3527872.
- [14] Zheng M, Wang C, Ali A, Shih YA, Xie Q, Guo C. Prevalence of Periodontitis in People Clinically Diagnosed with Diabetes Mellitus: A Meta-Analysis of Epidemiologic Studies. *Acta Diabetologica*. 2021 Oct; 58(10): 1307-27. doi: 10.1007/s00592-021-01738-2.
- [15] Shetty B, Divakar DD, Al-Kheraif AA, Alharbi AO, Almutairi MS, Alanazi MM. Role of PDT as an Adjunct to SRP on Whole Salivary RANKL and OPG ratio in Type-2 Diabetic and Normoglycemic Individuals with Chronic Periodontitis. *Photodiagnosis and Photodynamic Therapy*. 2021 Jun; 34: 2-8. doi: 10.1016/j.pdpdt.2021.102220.
- [16] Cosano LC, Pérez AR, Spinato S, Wainwright M, Machuca-Portillo G, Figallo MA et al. Descriptive Retrospective Study Analyzing Relevant Factors Related to Dental Implant Failure. *Medicina Oral, Patología Oral y Cirugía Bucal*. 2019 Nov; 24(6): 726-738.
- [17] Baeza M, Morales A, Cisterna C, Cavalla F, Jara G, Isamitt Y et al. Effect of Periodontal Treatment in Patients with Periodontitis and Diabetes: Systematic Review and Meta-Analysis. *Journal of Applied Oral Science*. 2020 Jan; 28: 1-13. doi: 10.1590/1678-7757-2019-0248.
- [18] Kumari S, Gnanasundaram N. Oral Manifestations in Diabetes Mellitus—A Review. *Journal of Indian Academy of Oral Medicine and Radiology*. 2021 Oct; 33(4): 352-6. doi: 10.4103/jiaomr.jiaomr\_325\_21.
- [19] Ramos-García P, González-Moles MÁ, González-Ruiz L, Ayén Á, Ruiz-Ávila I, Bravo M et al. Clinicopathological Significance of Tumor Cyclin D1 expression in Oral Cancer. *Archives of Oral Biology*. 2019 Mar; 99: 177-82. doi: 10.1016/j.archoralbio.2019.01.018.
- [20] Ravindranath NS and Raju R. Association of Oral Health Status and Oral Health-Related Quality of Life among Adult Patients with Type 2 Diabetes Mellitus: A Cross-Sectional Study. *Journal of Indian Association of Public Health Dentistry*. 2020 Oct; 18(4): 290-5. doi: 10.4103/jiaphd.jiaphd\_31\_20.
- [21] Ahmad P, Akhtar U, Chaudhry A, Rahid U, Saif S, Asif JA. Repercussions of Diabetes Mellitus on the Oral Cavity. *European Journal of General Dentistry*. 2019 Sep; 8(03): 55-62. doi: 10.4103/ejgd.ejgd\_28\_19.
- [22] Rohani B. Oral Manifestations in Patients with Diabetes Mellitus. *World Journal of Diabetes*. 2019 Sep; 10(9): 485-489. doi: 10.4239/wjd.v10.i9.485.