



Original Article



Involvement of Paranasal Sinuses in Patients with Bilateral Nasal Polyps: A Cross-Sectional Descriptive Study at Swabi

Jawad Badshah¹, Khalilullah², Asadullah³, Waseem Khan⁴, Arshad Abbas⁴, Saira Nizam⁵ and Syed Ihtisham Kakakhel⁶¹Department of ENT, ENT Care Centre, Timergara, Pakistan²Department of ENT, District Headquarters Hospital, Khar Bajaur, Pakistan³Department of ENT, Swat Medical Complex Teaching Hospital, Swat, Pakistan⁴Department of ENT, Gajju Khan Medical College, Swabi, Pakistan⁵Department of ENT, Government Hospital, Swabi, Pakistan⁶Department of Family Medicine, Bacha Khan Medical Complex, Swabi, Pakistan

ARTICLE INFO

Keywords:

Bilateral Nasal Polyps, Maxillary Sinuses, Ethmoid Sinuses, Sphenoid Sinuses

How to Cite:Badshah, J., Khalilullah, ., Asadullah, ., Khan, W., Abbas, A., Nizam, S., & Kakakhel, S. I. (2025). Involvement of Paranasal Sinuses in Patients with Bilateral Nasal Polyps: A Cross-Sectional Descriptive Study at Swabi: Paranasal Sinuses in Patients with Bilateral Nasal Polyps. *Pakistan Journal of Health Sciences*, 6(4), 44-49. <https://doi.org/10.54393/pjhs.v6i4.2776>***Corresponding Author:**Khalilullah
Department of ENT, District Head Quarter Hospital,
Khar Bajaur, Pakistan
khalilullahbmc@gmail.comReceived date: 15th January, 2025Revised date: 2nd April, 2025Acceptance date: 6th April, 2025Published date: 30th April, 2025

ABSTRACT

Non-neoplastic, pedunculated swellings of the sinonasal mucosa are called sinonasal polyps. They are called polyposis when they occur in multiple numbers. **Objectives:** To determine the frequency of paranasal sinus involvement in patients with bilateral nasal polyps aged 20-50 years using a validated self-structured questionnaire and radiological imaging. **Methods:** A cross-sectional descriptive study was conducted at the ENT Department of Bacha Khan Medical Complex, Swabi, from January 24, 2024, to June 23, 2024. A sample size of 50 patients was selected using a convenient sampling technique. Data were collected using a pre-tested, validated questionnaire, and sinus involvement was assessed via CT scans. Descriptive statistics were analyzed using SPSS version 26.0. **Results:** Among 50 patients, 72% (n=36) were male, and 28% (n=14) were female. The 20-25 age group constituted 30% (n=15) of the sample. Maxillary sinus involvement was most common (36%), followed by ethmoid (26%), frontal (26%), and sphenoid sinuses (18%). Bilateral maxillary sinus involvement was observed in 40% of patients. **Conclusions:** It was concluded that the study highlights the predominant involvement of maxillary sinuses in bilateral nasal polyps, emphasizing the need for comprehensive radiological evaluation to guide management. The findings align with existing literature but underscore the need for larger, randomized studies to improve generalizability.

INTRODUCTION

The uppermost portion of the upper respiratory system is made up of the nasal cavity and paranasal sinuses, which are pneumatic compartments that are connected to the atmosphere. These structures are located just below the cranium's base and are linked to a number of important structures. Due to its great exposure to airborne pollutants, this area is the site of some of the rarest and most complex benign and malignant diseases that humans may develop. Non-neoplastic, pedunculated swellings of the sinonasal mucosa are called sinonasal polyps. They are

called polyposis when they occur in multiple numbers. Although there are other reasons, such as viral, chemical, or hereditary aetiologies, most are inflammatory or allergic. Nasal polyps' histological characteristics don't always match their etiology [1]. The nose is the most apparent feature on the face and has both aesthetic and functional significance. In daily clinical practice, both neoplastic and non-neoplastic lesions of the nasal cavity and paranasal sinuses are frequently seen. They are frequently found in age groups in their second and third



decades. Nasal blockage, nasal discharge, epistaxis, face puffiness, headache, loss of smell, and orbital and ear problems are common initial signs of sinonasal lesions. The most frequent cause of nasal blockage is nasal polyps. Although their precise etiology is uncertain, they are primarily linked to aspirin sensitivity, allergies, asthma, and infections. According to histopathological analysis, some of the lesions are cancerous, while the majority are not. Inflammatory polyps were the most prevalent bilateral non-neoplastic lesions [2]. In both adults and children, unilateral polyps are uncommon and linked to a variety of disorders that require more research. Depending on the site and location, a polyp can be anatomically classified as ethmoidal or antrochoanal. Imaging tests are essential for determining the location and size of the nose and paranasal sinuses as well as for ruling out serious nasal disorders. Surgical intervention or medicine may be used as the treatment [3]. Polyps obstructing sinus ostia often involve the maxillary sinuses, resulting in sinus infections. Nasal polyps frequently originate in the ethmoid sinuses, and inflammation may spread to neighbouring sinuses. Sphenoid and Frontal Sinuses. Though less frequently affected, it can play a role in more complex situations, leading to issues including headaches. Visual disturbances [4]. Up to 40% of people are likely to develop nasal polyps at some point in their lives, and about 4% already have them. Males are more likely than girls to experience them, and they often happen after the age of 20. The term "nasal polyp" originates far to the Ancient Egyptians. In their survey, the age group most commonly involved (30%) was 31–40 years old, with 29.86% participating in the same age group [5]. The eosinophil-related cytokine IL-5 was significantly elevated in bilateral nasal polyposis. Different types of sinusitis seem to exhibit distinct cytokine 2.656 with cystic fibrosis had nasal polyps [6]. Churg–Strauss Syndrome, allergic fungal sinusitis, and cilia dyskinesia in nonallergic asthma versus allergic asthma (13% vs. 5%, $p < 0.01$) are other disorders linked to nasal polyps [7, 8]. Recurrences occur in about 40% of people who had surgical polypectomies. Nasal polyp development seems to have a genetic component. To standardize treatment, consider differential diagnosis and gather useful comparative research data, a categorization system for staging nasal polyps is suggested [9, 10]. 22 out of the 69 autopsies had nasal polyps, which is a 32% frequency. 54 polyps in total were discovered. Five polyps were huge, ten were medium-sized, and thirty-nine were small (length, 2–5 mm). No complaints of symptoms from the nasal polyps were noted. Most of the polyps, 40 of 54 (74%) developed in proximity to sinus outlets. The majority of these were located in the middle or superior meatus (13 of 54 [24%]; 34 of 54 [63%]) [11]. For functional endoscopic sinus surgery (FESS), a computed tomography (CT) scan of the paranasal

sinuses is crucial because the surgeon can utilize the information to arrange the procedure beforehand. A survey claims that all scans were performed using sagittal reconstruction and a 3 mm thickness in the axial and coronal planes. The sphenoid sinus was the least affected, but the maxillary sinus was the most frequently and seriously afflicted [12, 13]. Thirteen cadavers had polyps discovered after 31 underwent endoscopic endonasal surgery after a thorough examination of the nasal cavity and paranasal sinuses. A total of 27 polyps were discovered. Just four patients had a history of sinusitis or allergies. Photographs were taken to record the polyps and their origin. The ostia, clefts, or recesses were the origin of 70% of the polyps. Three patients developed polyps on the middle turbinate, and one patient developed them on the agger nasi area [14]. Nineteen victims had their naso-ethmoidal blocks removed in the autopsy material. No rhinoscopy had been performed on any of the patients previously. The sphenoidal and maxillary sinuses were accessed and examined for polyps before excision. The entire naso-ethmoidal complex was closely inspected for nasal polyps following excision. The specific polyp's place of origin was registered and captured on camera. Five patients, four of whom had no prior history of sinusitis, asthma, or allergies, had nine polyps. Three patients had bilateral polyps, while two individuals had unilateral solitary polyps. The meatus included all of the polyps. 89% of the polyps were associated with ethmoid clefts. The ethmoidal and other paranasal sinuses did not contain any polyps [15]. In a study in which the evaluation of the structure and etiology of nasal polyps, as well as key characteristics from surgical investigations, autopsy studies, and histopathologic analyses were discussed, despite the fact that much is still unknown about them and their origin. It was discovered that 75% of nasal polyps were related to ethmoidal recesses and clefts, that the majority of the polyps were unilateral (63%), and that 37% of the cadavers had bilateral nasal polyps [16]. Key limitations of current imaging techniques, like CT scans, in diagnosing nasal polyps include poor soft tissue differentiation, inability to distinguish inflammatory from neoplastic lesions, and limited functional assessment. Improvements may include integrating MRI for better soft tissue contrast and incorporating advanced imaging protocols or AI-based analysis for enhanced classification and treatment planning.

Bilateral nasal polyps are a common sinonasal disorder associated with chronic inflammation and significant morbidity, yet there is limited localized evidence on the specific pattern and frequency of paranasal sinus involvement in affected patients, particularly in Pakistani populations. Most previous studies have focused broadly on nasal polyposis, symptomatology, or treatment

outcomes, with insufficient emphasis on detailed radiological evaluation of sinus-specific involvement such as maxillary, ethmoid, frontal, and sphenoid sinuses in regional clinical settings. This research gap restricts evidence-based diagnostic and management planning for local healthcare systems. Therefore, this study aimed to determine the frequency and distribution of paranasal sinus involvement in patients aged 20–50 years with bilateral nasal polyps using validated questionnaires and CT imaging, while identifying the most commonly affected sinuses to strengthen clinical understanding and improve management strategies.

METHODS

A cross-sectional descriptive study was conducted at the ENT Department of Bacha Khan Medical Complex, Swabi, from January 24, 2024, to June 23, 2024. The sample size was calculated using the standard formula for a cross-sectional study: $n = Z^2 \cdot p \cdot (1-p) / d^2$, taking prevalence of nasal polyps in population as 0.5% ($p=0.5$), 95% confidence level ($Z=1.96$), and 5% margin of error ($d=0.05$), the minimum required sample size was 8 [17]. However, to increase the generalizability of results, a convenient sample of 50 patients was included, which is acknowledged as a limitation of the study. A convenient sampling technique was used to recruit 50 patients aged 20–50 years. The sample size was determined based on feasibility, although a formal power analysis was not conducted. Inclusion Criteria: Patients aged 20–50 years with bilateral nasal polyps confirmed by clinical and radiological evaluation. Exclusion Criteria: Patients outside the specified age range, immunocompromised individuals, those on long-term steroids, and those with fungal infections. A self-structured questionnaire was developed, pre-tested, and validated for reliability (Cronbach's alpha = 0.85) and accuracy. Data on demographic characteristics, clinical symptoms, and sinus involvement were collected. CT scans were performed using standardised protocols and interpreted by a single radiologist to ensure consistency. Ethical approval was obtained from the Institutional Review Board of Bacha Khan Medical Complex (Ref: 26019/ERB/GKMC/BKMC Swabi). Written informed consent was obtained from all participants, and patient confidentiality was maintained throughout the study. Data were analysed using SPSS version 26.0. Descriptive statistics (frequencies and percentages) were used to summarize the data. Inferential statistics, such as chi-square tests, were planned but not performed due to the small sample size. A randomized sampling approach would reduce bias and improve the external validity of the study. The study relied solely on descriptive statistics and did not perform inferential tests (e.g., chi-square or t-tests) to assess associations or differences. Including inferential statistics would provide stronger evidence for the

observed findings. The study restricted the age range to 20–50 years without providing a clear rationale. This exclusion may limit the applicability of the findings to other age groups, such as adolescents or older adults, who may also present with bilateral nasal polyps. The exclusion of immunocompromised patients and those on long-term steroids may limit the generalizability of the results, as these groups are often at higher risk for sinonasal diseases. Including these populations would provide a more comprehensive understanding of sinus involvement in bilateral nasal polyps. The study did not account for potential confounders such as smoking, environmental exposures (e.g., air pollution), or occupational hazards, which are known to influence sinonasal health. Controlling for these factors would strengthen the validity of the findings. The study did not specify whether CT scan interpretations followed standardized criteria or involved multiple radiologists to assess inter-observer variability. Standardized protocols and multiple observers would improve the accuracy and reliability of radiological findings. The study design was described as cross-sectional but lacked a clear hypothesis or justification for this approach. A more robust study design, such as a longitudinal or case-control study, could provide deeper insights into the causal relationships and progression of sinus involvement in bilateral nasal polyps. While ethical approval was obtained, the study did not detail how patient confidentiality and data security were maintained. Providing this information would enhance the transparency and ethical rigor of the study. The small sample size ($n=50$) and convenient sampling technique limit the generalizability of the findings to broader populations. Future studies should aim for larger, more diverse samples to improve external validity.

RESULTS

There were 50 patients in the study. 36 (72%) were male and 14 (28%) were female. 15 (30%) were aged 20–25 years and followed by 8 (16%) aged 36–40 years. Sinus involvement was Maxillary Sinus: 36% involvement, with bilateral involvement in 40% of cases. Ethmoid Sinus: 26% involvement, with bilateral involvement in 26% of cases. Frontal Sinus: 26% involvement, with bilateral involvement in 26% of cases. Sphenoid Sinus: 18% involvement, with bilateral involvement in 18% of cases. Demographic characteristics of the patients are shown in Table 1.

Table 1: Demographic Characteristics of the Patients

Characteristics		Frequency (%)
Gender	Male	36 (72%)
	Female	14 (28%)
Age	20–25 Years	15 (30%)
	36–40 Years	8 (16%)
Sinus Involvement	Maxillary Sinus	36%
	Ethmoid Sinus	26%

	Frontal Sinus	26%
	Sphenoid Sinus	18%

Amongst the age group involved, most patient were amongst age group 20-25 years as shown in table 2.

Table 2: Age Wise Distribution

Variables		Frequency (%)
Gender	20-25	15 (30%)
	26-30	7 (14%)
	31-35	7 (14%)
	36-40	8 (16%)
	41-45	6 (12%)
	46-50	7
	Total	50

A pie charts of sinuses involvement in bilateral nasal polyps with maxillary sinuses most commonly involved in about 36.00% patients in the figure 1.

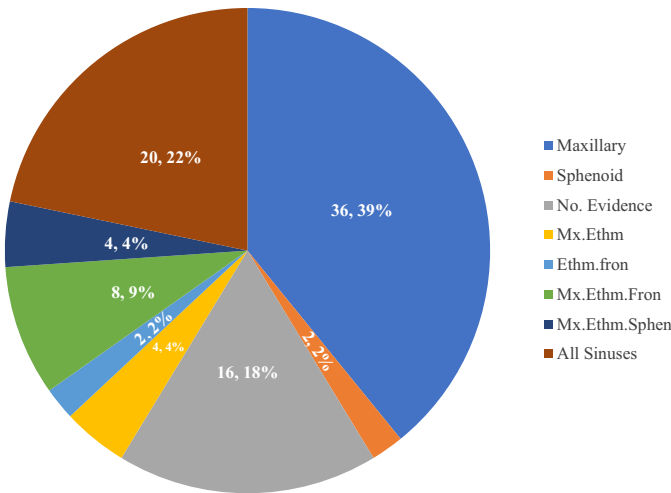


Figure 1: Involvement of Sinuses

Frequency of maxillary sinus involvement having 16% of left sinus, 22% of right sinus and 40% of both involvement while 22% of no involvements, as shown in figure 2.

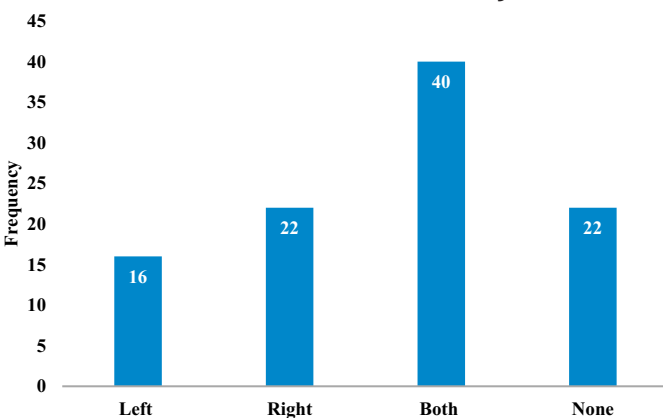


Figure 2: Side of Maxillary Sinus Involvement

Frequency of ethmoidal sinuses involvement having 8% left ,6% right ,26% both and about 60% of no evidence is shown in figure 3.

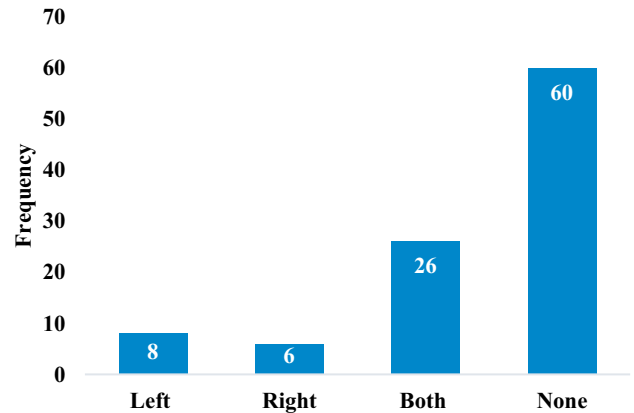


Figure 3: Side of Ethmoidal Sinus Involvement

The frequency of frontal involvement, having 8% left,4% right, 26% both and 62% none, is shown in figure 4.

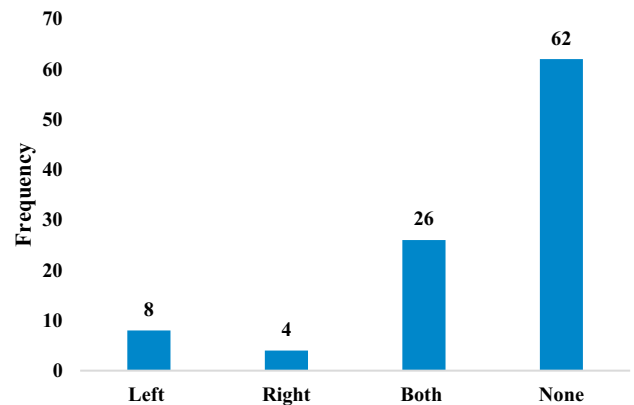


Figure 4: Side of Frontal Sinus Involvement

The frequency of sphenoid sinus with 4% left,6% right, 18% both, and 72% none, are shown in figure 5.

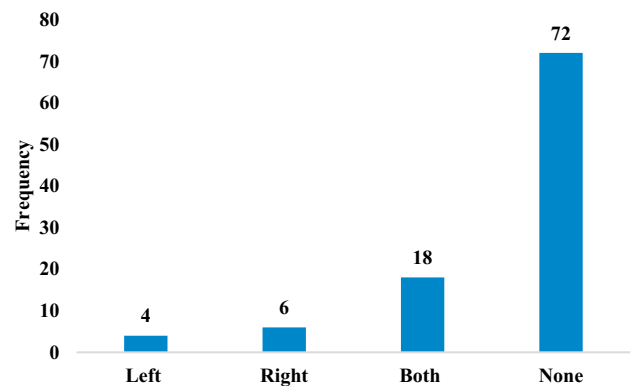


Figure 5: Side of Sphenoid Sinus Involvement

DISCUSSION

The study findings highlight the predominant involvement of maxillary sinuses in bilateral nasal polyps, consistent with their anatomical predisposition to inflammatory processes. The ethmoid, frontal, and sphenoid sinuses showed lower frequencies of involvement, likely due to their complex drainage pathways and reduced exposure to inflammatory stimuli. These results align with previous

studies, such as Kwah, who reported maxillary sinus involvement in 65% of cases. However, the higher prevalence in the 20–25 age group in our study contrasts with the typical peak in the fourth decade, possibly due to regional or environmental factors. Similar finding was reported in study in which Nasal polyps are inflammatory outgrowths of paranasal sinus mucosa caused by chronic mucosal inflammation and are present in 20% of patients [18]. The maxillary sinuses were involved in 36% of patients, with bilateral involvement (40%) being the most frequent, followed by right-side involvement (22%) and left-side involvement (16%). Interestingly, 22% of patients showed no maxillary sinus involvement. This pattern suggests that bilateral nasal polyps frequently extend to both maxillary sinuses, likely due to the central role of the maxillary sinuses in sinonasal drainage. A comparable study conducted in Denmark reveals a ratio of 2.74:1, with 73.27% of the population being male and 26.73% being female. The mean age of the maxillary sinus polyps was 38.55 + 13.44 years, and they were observed in the 11–79 age range. 93.10% of patients had unilateral maxillary sinus polyps, while 6.90% had bilateral ones. The right side of 54.31% of patients had polyps, while the left side had 38.79% [19]. The ethmoid sinuses demonstrated a moderate frequency of involvement, with 26% showing bilateral disease, while unilateral involvement was relatively less common (8% left, 6% right). Notably, 60% of patients had no evidence of ethmoid sinus involvement. This finding may indicate a less consistent association of nasal polyps with ethmoidal sinus disease, possibly due to the variability in the severity and extent of inflammation. Involvement of the frontal sinuses was observed in 26% of patients bilaterally, with unilateral involvement being less common (8% left, 4% right). However, 62% of patients exhibited no frontal sinus involvement, suggesting that the frontal sinuses are less frequently implicated in bilateral nasal polyp cases, possibly due to their more complex drainage anatomy and less direct exposure to inflammatory processes. A similar study in Virginia shows that the major causes for frontal sinusitis were polyp (53%) in the frontal sinuses [20]. The sphenoid sinuses were the least frequently involved, with only 18% showing bilateral disease and 4% left and 6% right unilateral involvement. A significant proportion of patients (72%) showed no sphenoid sinus involvement. This finding is consistent with the anatomical position and lower susceptibility of the sphenoid sinuses to primary inflammatory processes compared to other paranasal sinuses. Another study conducted shows that the origin of the polyps was the maxillary sinus in 65 patients, the sphenoid sinus in six, the middle turbinate in two, the septum in two, and the ethmoid sinus in one, based on their localizations [21]. The study was limited by its small sample size, convenient non-random sampling, single-center design, and dependence primarily on descriptive statistics, which may reduce external validity and broader applicability.

Exclusion of certain patient groups and lack of confounder analysis further limit comprehensive interpretation. Future studies should involve larger multicenter populations, randomized sampling methods, inferential statistical analyses, and broader demographic inclusion to provide more reliable, generalizable, and clinically impactful findings.

CONCLUSIONS

The study highlights the involvement of various paranasal sinuses in patients diagnosed with bilateral nasal polyps. Among the paranasal sinuses, the maxillary and ethmoid sinuses were most commonly affected, reflecting their close anatomical relationship with the nasal cavity and susceptibility to inflammatory processes. The frontal and sphenoid sinuses demonstrated less frequent involvement, suggesting variability in the extent of disease progression. These findings underline the importance of comprehensive radiological evaluation in patients with bilateral nasal polyps to accurately assess sinus involvement and guide effective management strategies. Early diagnosis and targeted treatment could potentially reduce complications and improve patient outcomes. Further research is recommended to explore the relationship between sinus involvement and disease severity, as well as the impact of therapeutic interventions.

Authors' Contribution

Conceptualization: JB

Methodology: JB, K, WK, AB, SN, SIK

Formal analysis: AB

Writing and Drafting: A, WK

Review and Editing: JB, K, WK, AB, SN, SIK

All authors approved the final manuscript and take responsibility for the integrity of the work

Conflicts of Interest

All the authors declare no conflict of interest.

Source of Funding

The author received no financial support for the research, authorship and/or publication of this article.

REFERENCES

- [1] Cardesa A, Alos L, Nadal A, Franchi A. Nasal Cavity and Paranasal Sinuses. *Pathology of the Head and Neck*. 2016:49-127. doi: 10.1007/978-3-662-49672-5_2.
- [2] Nee TS and Abdullah B. Nasal Cavity and Paranasal Sinus Malignancy. *Head and Neck Malignancy: Highlights of Clinical Presentation, Assessment and Treatment*. 2023 Nov.
- [3] Olajuyin OA and Olajide TG. Patterns, Presentations and Prognosis of Nasal Polyps. *Indian Journal of Otolaryngology and Head and Neck Surgery*. 2019 Nov; 71:1770-4. doi:10.1007/s12070-017-1119-0.

- [4] Stevens WW, Schleimer RP, Kern RC. Chronic Rhinosinusitis With Nasal Polyps. *The Journal of Allergy and Clinical Immunology: In practice*. 2016 Jul; 4(4):565-72. doi: 10.1016/j.jaip.2016.04.012.
- [5] Bachert C, Wagenmann M, Rudack C, Höpken K, Hildebrandt M, Wang D et al. The Role of Cytokines in Infectious Sinusitis and Nasal Polyposis. *Allergy*. 2007 Apr; 53(1): 2. doi: 10.1111/j.1398-9995.1998.tb03767.x.
- [6] Laidlaw TM, Mullol J, Woessner KM, Amin N, Mannent LP. Chronic Rhinosinusitis with Nasal Polyps and Asthma. *The Journal of Allergy and Clinical Immunology: In Practice*. 2021 Mar; 9(3):1133-41. doi: 10.1016/j.jaip.2020.09.063.
- [7] Singh NK and Raza K. Progress in Deep Learning-Based Dental and Maxillofacial Image Analysis: A Systematic Review. *Expert Systems with Applications*. 2022 Aug; 199:116968. doi:10.1016/j.eswa.2022.116968.
- [8] Bolk KG, Edwards TS, Wise SK, DelGaudio JM. Allergy and Asthma Prevalence and Management Across Nasal Polyp Subtypes. *Otolaryngologic Clinics of North America*. 2024 Apr; 57(2):253-63. doi:10.1016/j.otc.2023.09.001.
- [9] Lee JH. A Polyp Originating in the Middle Turbinate and Extending to the Maxillary Sinus Ostium. *Ear, Nose and Throat Journal*. 2018 Aug; 97(8):E48-9. doi:10.1177/014556131809700811.
- [10] Altunay ZO and Önerci TM. Reasons for Failure and Complications of Surgery in Diffuse Nasal Polyposis. In *Nasal Polyposis and Its Management: Pathogenesis, Medical and Surgical Treatment*. Cham: Springer International Publishing. 2024 Jul:331-344. doi:10.1007/978-3-031-33199-2_34.
- [11] Arsalan D, Syed SH, Murtaza G, Nasir MQ, Amin MA, Awan AA. The Frequency of Intranasal Synechiae Formation between Nasal Septum and Lateral Nasal Wall After Endoscopic Sinus Surgery Among Patients with Sinonasal Polyposis. *Esculapio Journal of SIMS*. 2020; 16(3). doi: 10.51273/esc20.2516316.
- [12] Varshney H, Varshney J, Biswas S, Ghosh SK. Importance of CT Scan of Paranasal Sinuses in the Evaluation of the Anatomical Findings in Patients Suffering from Sinonasal Polyposis. *Indian Journal of Otolaryngology and Head and Neck Surgery*. 2016 Jun; 68:167-72. doi:10.1007/s12070-015-0827-6.
- [13] Schneider S, Campion NJ, Villazala-Merino S, Liu DT, Bartosik T, Landegger LD et al. Associations between the Quality of Life and Nasal Polyp Size in Patients Suffering from Chronic Rhinosinusitis without Nasal Polyps, with Nasal Polyps Or Aspirin-Exacerbated Respiratory Disease. *Journal of Clinical Medicine*. 2020 Mar; 9(4): 925. doi: 10.3390/jcm9040925.
- [14] Goulioumis AK, Kourelis K, Gkorpa M, Danielides V. Pathogenesis of nasal polyposis: current trends. *Indian Journal of Otolaryngology and Head and Neck Surgery*. 2023 Apr; 75(Suppl 1):733-41. doi:10.1007/s12070-022-03247-2.
- [15] Sedaghat AR, Kuan EC, Scadding GK. Epidemiology of Chronic Rhinosinusitis: Prevalence and Risk Factors. *The Journal of Allergy and Clinical Immunology: In Practice*. 2022 Jun; 10(6):1395-403. doi:10.1016/j.jaip.2022.01.016.
- [16] Sommer F. Rare Diseases of the Nose, The Paranasal Sinuses, and the Anterior Skull Base. *Laryngo-Rhino-Otologie*. 2021 Apr; 100(Suppl 1): S1.
- [17] Alqurashi AM, Jawmin SA, Althobaiti TA, Aladwani MN, Almuebid AM, Alharbi JF et al. An Overview on Nasal Polyps' Diagnosis and Management Approach. *World Journal of Environmental Biosciences*. 2022; 11(1-2022):13-6. doi: 10.51847/gde2of0va0.
- [18] Kwah JH and Peters AT. Nasal Polyps and Rhinosinusitis. In *Allergy and Asthma Proceedings*. 2019 Nov; 40(6). doi:10.2500/aap.2019.40.4252.
- [19] Tos M, Larsen PL, Larsen K, Caye-Thomasen P. Pathogenesis and Pathophysiology of Nasal Polyps. In *Nasal Polyposis and Its Management: Pathogenesis, Medical and Surgical Treatment*. Cham: Springer International Publishing. 2024 Jul:65-77. doi:10.1007/978-3-031-33199-2_8.
- [20] Fawzi NE, Lazim NM, Aziz ME, Mohammad ZW, Abdullah B. The Prevalence of Frontal Cell Variants According to the International Frontal Sinus Anatomy Classification and Their Associations with Frontal Sinusitis. *European Archives of Oto-Rhino-Laryngology*. 2022 Feb; 279(2): 765-71. doi: 10.1007/s00405-021-06843-0.
- [21] İla K, Topdağ M, Öztürk M, İşeri M, Aydın Ö, Keskin G. Retrospective Analysis of Surgical Treatment of Choanal Polyps. *The Turkish Journal of Ear, Nose, and Throat*. 2015; 25(3):144-51. doi:10.5606/kbbihtisas.2015.68878.